

Original Article

Diagnostic Role of Fine Needle Aspiration Cytology in Wilms' Tumour

Alam K*, Prasad S⁺⁺, Maheshwari V[#], Aggarwal S^{**}, Chana RS⁺⁺

Abstract

A ten year retrospective study of 34 cases of Wilms' tumour in children is presented with 24 cases (70.5%) in the age group 0-5 years and a mean age of 4 years. A male: female ratio of 4.7:1 was seen. All the children presented with lump in abdomen, constitutional symptoms in addition were observed in 6 cases. Bilateral tumour was seen in 2 (5.8%) cases. A histocytomorphological correlation with regards to the differential diagnosis of small round cell tumours of childhood in abdominal cavity is discussed. The differential diagnosis of Wilms' tumour includes malignant round cell tumours such as neuroblastoma, non-Hodgkins lymphoma, rhabdomyosarcoma and other pediatric renal tumours such as mesoblastic nephroma, cystic nephroma, rhabdoid tumour and clear cell sarcoma. In cases with high clinical suspicion of Wilms' tumour, where preoperative chemotherapy and radiotherapy are indicated, fine needle aspiration cytology (FNAC) can act as a reliable diagnostic tool to complement the clinical diagnosis.

Journal of Cytology 2007; 24 (3) : 134-136

Key Words: Wilms' tumour, small round cell tumour, FNAC.

Introduction

Primary renal tumours constitute the fourth commonest solid tumours of childhood, Wilms' tumour along with neuroblastoma being the two most common malignant round cell tumours of abdominal cavity.¹ In this report we will discuss the cytomorphological features of Wilms' tumour, keeping in mind the differential diagnosis of small round cell tumours of childhood in the abdominal cavity.

Material and Methods

A ten years retrospective study was undertaken on children aged between 0-14 years, coming to the pediatric clinics with abdominal lumps. Ultrasound guided fine needle aspiration cytology (FNAC) of the lumps was done on the 34 cases that were encountered. Slides were stained with Papanicolaou (PAP), Haematoxylin and Eosin (H&E), and May-Grünwald Giemsa (MGG) stains. Histopathological

correlation was done in 16 cases where nephrectomy was performed. Six patients left against medical advice. The remaining 12 patients underwent chemo-radiotherapy and were later referred to some higher centers for further treatment.

Observations

There were 34 cases of Wilms' tumour. The age varied with the youngest patient being seven months and the oldest 14 years. A maximum of 24 (70.5%) cases were observed in the 0-5 year age group. The mean age of the patients was 4 years, with an M: F ratio of 4.7:1. All patients presented with lump in abdomen. Other symptoms like pain, fever and loss of weight were observed in 6 cases. There were two cases (5.8%) of bilateral Wilms' tumour.

Cytology : Smears showed good cellularity with a triphasic pattern of varying combinations of blastemal, epithelial and stromal elements along with necrosis, inflammatory cells and rosettes (Fig.1a).

*Lecturer, ⁺Clinical Pathologist, [#]Professor, ^{**}Junior Resident, The Department of Pathology; ⁺⁺Professor, Department of Paediatric Surgery; J.N. Medical College, AMU, Aligarh.

Received: 02.04.2007; **Revised:** 25.07.2007; **Accepted:** 30.07.2007

Corresponding Author: Dr. Veena Maheshwari, 2/82, Arya Nagar, Avantika Part-2, Ramghat Road, Aligarh-202001 (U.P.)

E-mail: saanjuli@yahoo.co.uk

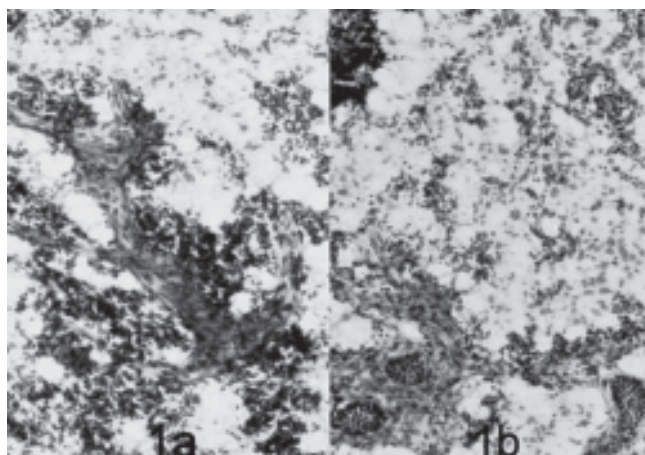


Fig.1: FNAC: a) Smear showing combination of blastemal, stromal and epithelial elements (Pap x 125); b) Smear showing blastemal cells, spindle shaped mesenchymal cells and tubule like epithelial elements (Pap x 125).

Blastemal cells were represented by small round cells with scant cytoplasm and round nuclei with evenly dispersed chromatin. Epithelial elements were seen forming solid strands, sheets, tubules and at places forming rosettes (Fig.1b). Stromal cells were spindle shaped with elongated nuclei arranged in bundles. Areas of necrosis and inflammatory cells including polymorphonuclear leucocytes, lymphocytes, macrophages with cellular debris and some eosinophils were seen. Anaplasia was not seen in any of our cases.

Gross : Nephrectomy was done in 16 cases. The kidney was enlarged in all cases (mean size 14x11 cm). Cut section revealed greyish white, homogenous, circumscribed mass with a fish flesh appearance in most cases (64.7%); while the rest showed renal lumps with irregular contours of similar appearance.

Histopathology: Sections revealed any of the three components viz. blastemal, epithelial and stromal in different combinations. The various patterns observed were triphasic (all three) in 24 cases (70.5%), biphasic (blastemal and stromal) in 8 (23.5%) and monophasic (blastemal only) in 2 (5.8%) cases. Epithelial elements showed differentiation in the form of abortive glomeruli, rosettes and tubules (Fig.2). Rhabdomyoblasts were seen in 6 cases, smooth muscle in 6, inflammatory cells and necrosis in 10 cases (Table 1). Calcification was observed in 2 cases.

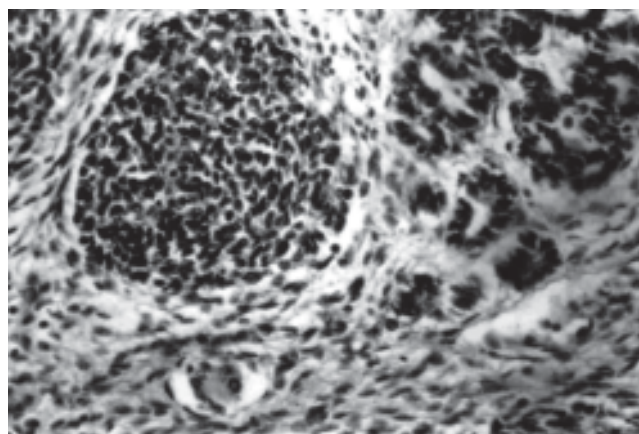


Fig.2: Histology: Section showing blastemal cells, stromal cells and immature tubule formation (H&E x 125).

Capsular infiltration was seen in 8 (23.5%) cases. There was no complication caused by fine needle aspiration in any of the cases.

Discussion

Over the last few years' FNA has been used more extensively in the diagnosis of pediatric solid tumours. A diagnostic sensitivity of 76-95% and a specificity of 80-100% has been claimed.² FNA under ultrasound guidance is preferred for abdominal malignancies.³ Ultrasound is useful especially in children for visualizing the needle and ensuring its accurate placement.⁴ However, one of its criticism is that it can cause tumour spillage which can be avoided by employing a postero-lateral approach.

In our study, male preponderance was observed, and 70.5% of our cases occurred in 0-5 year age group with a mean age of 4 years similar to the observation made by other authors.^{1,5} Bilaterality was seen in 5.8% cases, consistent with findings of Stiller et al (3-6%),⁵ and Joshi (5%).¹

FNAC revealed varying combinations of blastemal, stromal and epithelial elements consistent with observation made by other authors.^{7,8} In the present series, anaplastic Wilms' tumour was not encountered. Its presence is of prognostic significance as anaplasia is indicative of poor prognosis.⁹ Mishra et al¹⁰ reported anaplasia in 1.5% of cases in a series of 125 North Indian children while Beckwith¹¹ reported it as 5%.

Table 1 : Cytological analysis of various components in Wilms' tumour

Cells	Blastemal	Epithelial	Stromal	Necrosis	Inflammatory	Rosette
No. of cases	34	12	24	10	10	4
Percentage	100	37.5	75	31.25	31.25	12.5

Cyto-histological correlation was possible in 16 cases where nephrectomy specimen was available. The cytological diagnosis correlated with histological diagnosis in all of the cases, thus giving a 100% diagnostic accuracy. Blastemal component was seen uniformly in all cases on both histology and cytology. Lawler et al¹² and Wigger¹³ reported that presence of extensive tubular and glomerular differentiation and rhabdomyoblasts in large number carries a better prognosis.

The differential diagnosis of Wilms' tumour includes malignant round cell tumours such as neuroblastoma, non-Hodgkins lymphoma, rhabdomyosarcoma and other pediatric renal tumours such as mesoblastic nephroma, cystic nephroma, rhabdoid tumour and clear cell sarcoma.

Smears with predominant blastemal component may be mistaken for neuroblastoma. But the rosettes of neuroblastoma are multilayered and contain central, pink delicate fibrillary material representing neuropil. This is often not evident in cytologic smears but can be identified easily in cell blocks made from the aspirate.¹⁴ Tumour cells in non-Hodgkins lymphoma are round, monomorphic, discrete and do not form clusters. Lymphoglandular bodies may be present in the background. The cells are also positive for common leucocyte antigen (CLA).¹⁵

Differentiating Wilms' tumour from rhabdomyosarcoma may pose a problem since rhabdomyoblasts can be found in both lesions,¹⁵ but the presence of bimodal population of cells in smears and localization of tumour in kidney by imaging techniques would favour a diagnosis of Wilms' tumour.

The differential diagnosis of cystic nephroma and partially differentiated cystic nephroblastoma should be considered especially if fluid is aspirated.¹⁶

To conclude, FNAC can contribute in early diagnosis of Wilms' tumour, particularly in cases with high clinical suspicion and where pre-operative chemotherapy and radiotherapy are indicated.

References

1. Joshi VV. Pathology of Wilms' tumour in children. In: Proceedings of XIIth International CME in surgical pathology and cytology held at Pune- 18- 20th January, 2007, pp.18- 26.
2. Verdeguer A, Castel V, Torres V, et al. Fine needle aspiration biopsy in children: experience in 70 cases. *Med Pediatr Oncol* 1988; 16: 98-100.
3. Civardi G, Fornari F, Cowanna L, et al. Ultrasonically guided fine needle aspiration biopsy (UG-FNAB). A useful technique for diagnosis of abdominal malignancies. *Eur J Clin Oncol* 1986; 22: 225-7.
4. Van Sonnenberg E, Willich GR, Edwards DR, et al. Percutaneous diagnostic and therapeutic interventional radiologic procedures in children: experience in 100 patients. *Radiology* 1987; 162: 601-5.
5. Sharma S, Nath P, Srivastava AN, Singh KM. Wilm's tumour. A clinicopathologic study with special reference to its morphological variants. *Indian J Pathol Microbiol* 1995; 38: 55-62.
6. Stiller CA, Parkin DM. International variations in the incidence of childhood renal tumours. *Br J Cancer* 1990; 62: 1026-30.
7. Akhtar M, Ali MA, Burgess A, Hui M, Bakry K. Fine needle aspiration biopsy diagnosis of pediatric neoplasms. *Ann Saudi Med* 1991; 11: 366-76.
8. Quiyano G, Drut R. Cytologic characteristics of Wilm's tumour in fine needle aspirates: a study of ten cases. *Acta Cytol* 1989; 33: 263-6.
9. Bonadio JF, Slover B, Narkool P, et al. Anaplastic Wilm's tumour: clinical and pathologic studies. *J Clin Oncol* 1985; 3: 513-20.
10. Mishra K, Mathur M, Logani KB, et al. Precursor lesions of Wilm's tumour in Indian children. A multi institutional study. *Cancer* 1988; 83: 2228-32.
11. Beckwith JB. National Wilm's tumour study. An update for pathologists. *Pediatr Develop Pathol* 1998; 79-89.
12. Lawler W, Marsden HB, Palme MK. Wilm's tumour histologic variation and prognosis. *Cancer* 1975; 36: 1122-6.
13. Wigger HJ. Fetal rhabdomyomatous nephroblastoma: a variant of Wilm's tumour. *Hum Pathol* 1976; 7: 613-26.
14. Orell SR, Sterrett GF, Walters MN, Whitaker D. In: Manual and atlas of fine needle aspiration cytology. Edinburgh:Churchill Livingstone; 1986. p.146-81.
15. Layfield LJ, Glasgow B, Ostrzega N, Reynolds CP. Fine needle aspiration cytology and the diagnosis of neoplasms in the pediatric age group. *Diagn Cytopathol* 1991; 7: 451-61.
16. Joshi VV, Beckwith JB. Multilocular cyst of the kidney (cystic nephroma) and cystic, partially differentiated nephroblastoma. Terminology and criteria for diagnosis. *Cancer* 1989; 64: 466-79.