

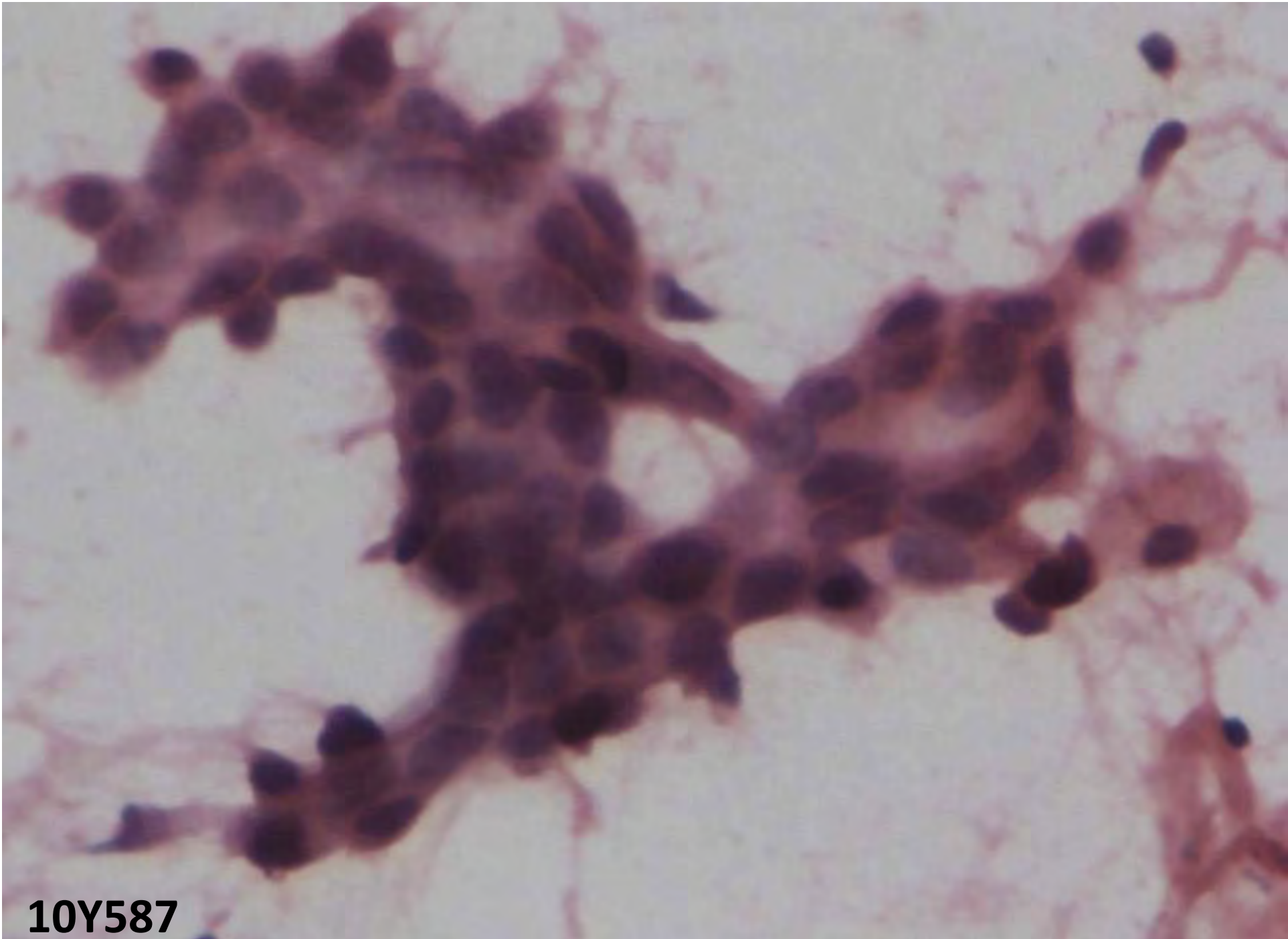
Ernest Fernandes Slide Seminar

CYTOCON 2011

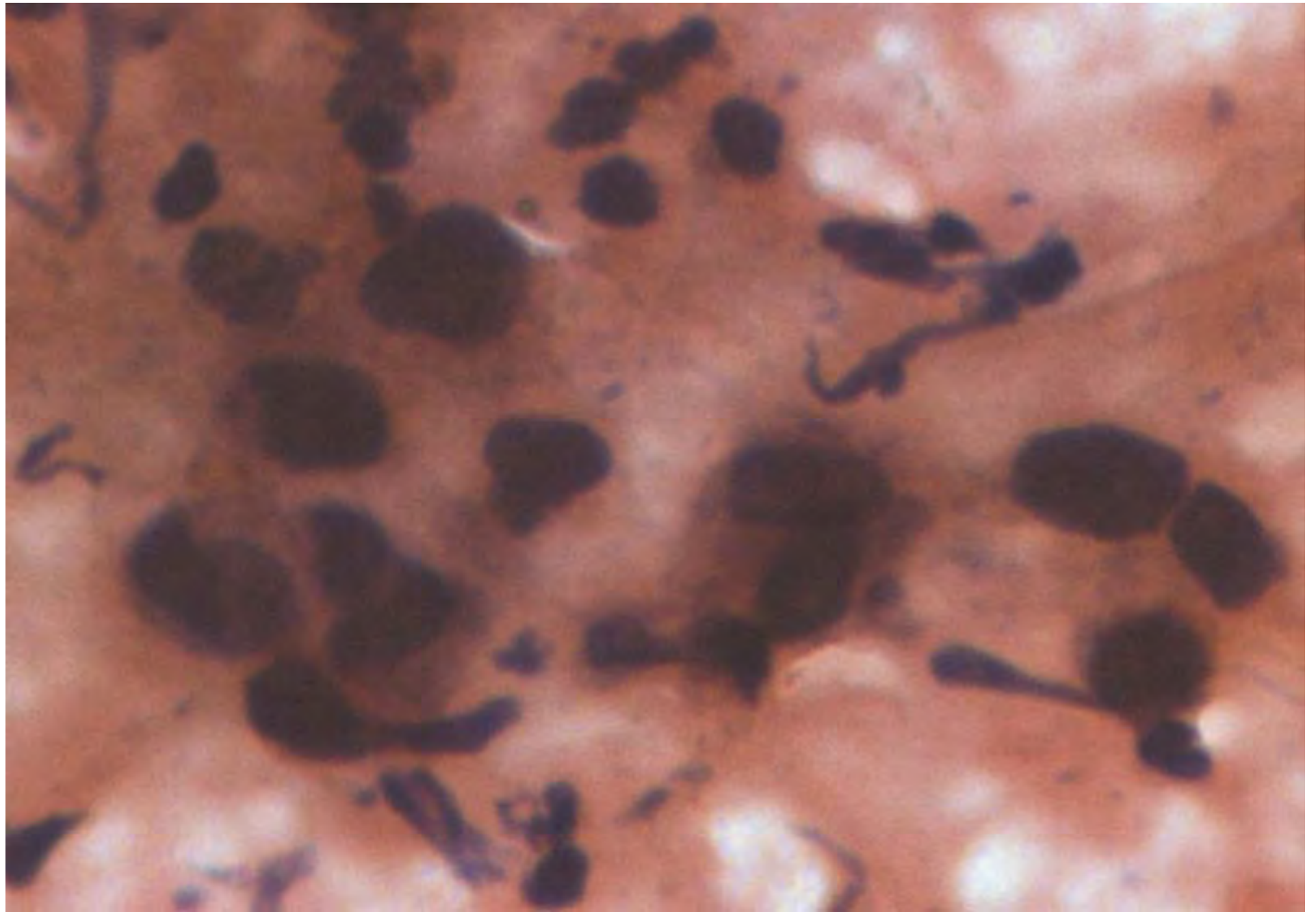
Aruna Prayaga

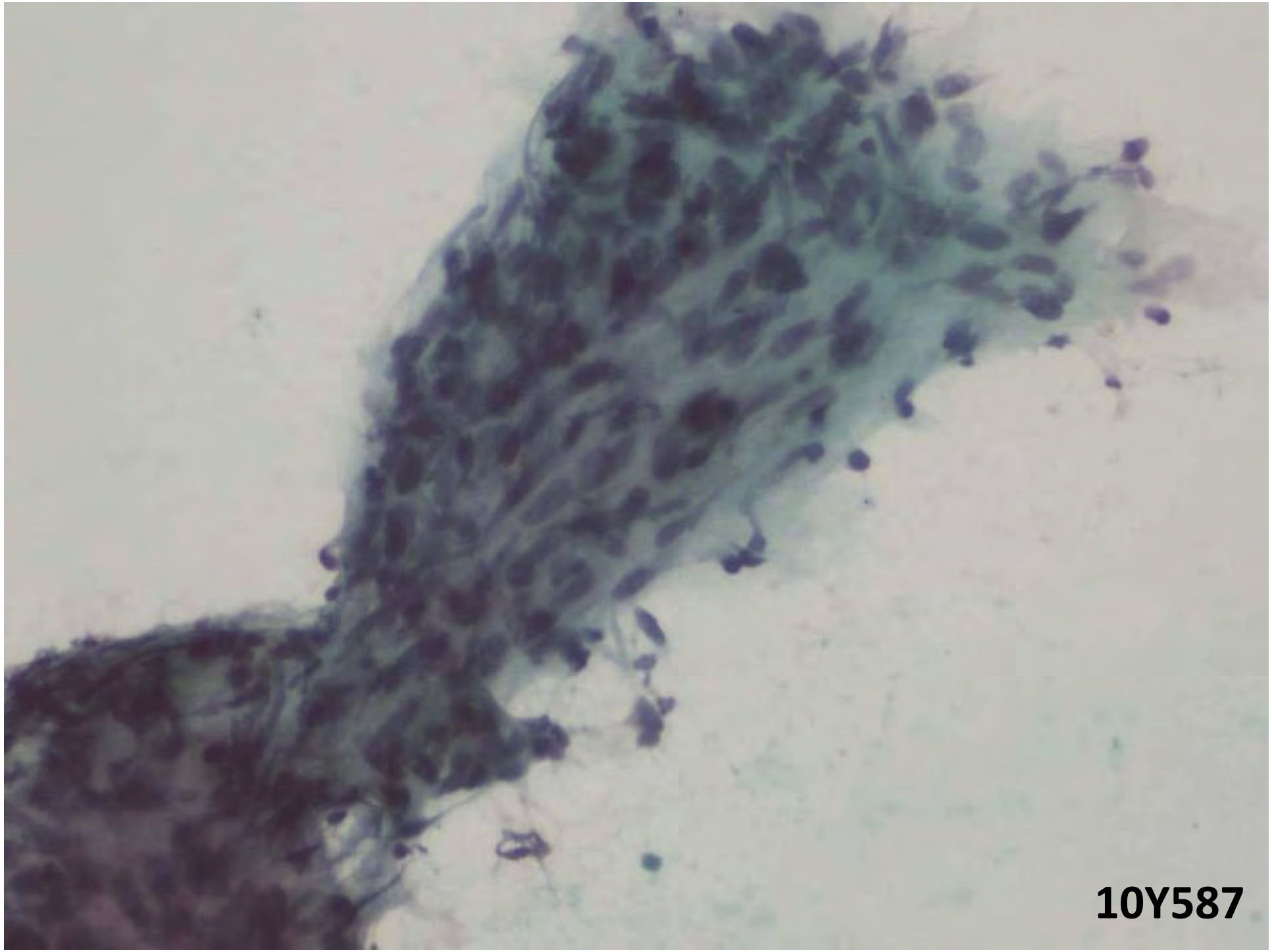
Case 1

- 50/F
- Left breast lump with pain
- Upper outer quadrant
- Firm mobile 3 X 3 cm
- No skin involvement
- No lymphadenopathy



10Y587

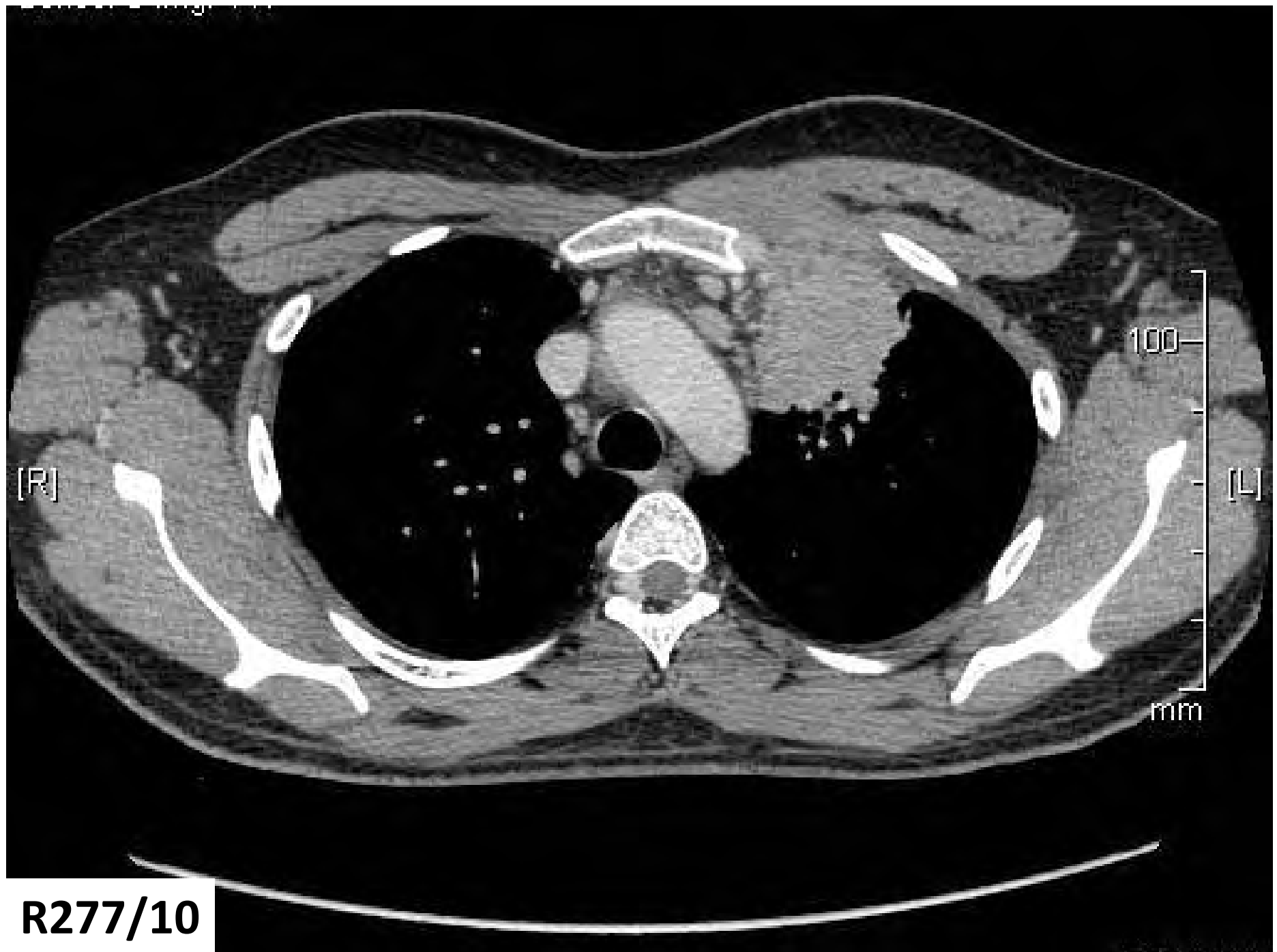


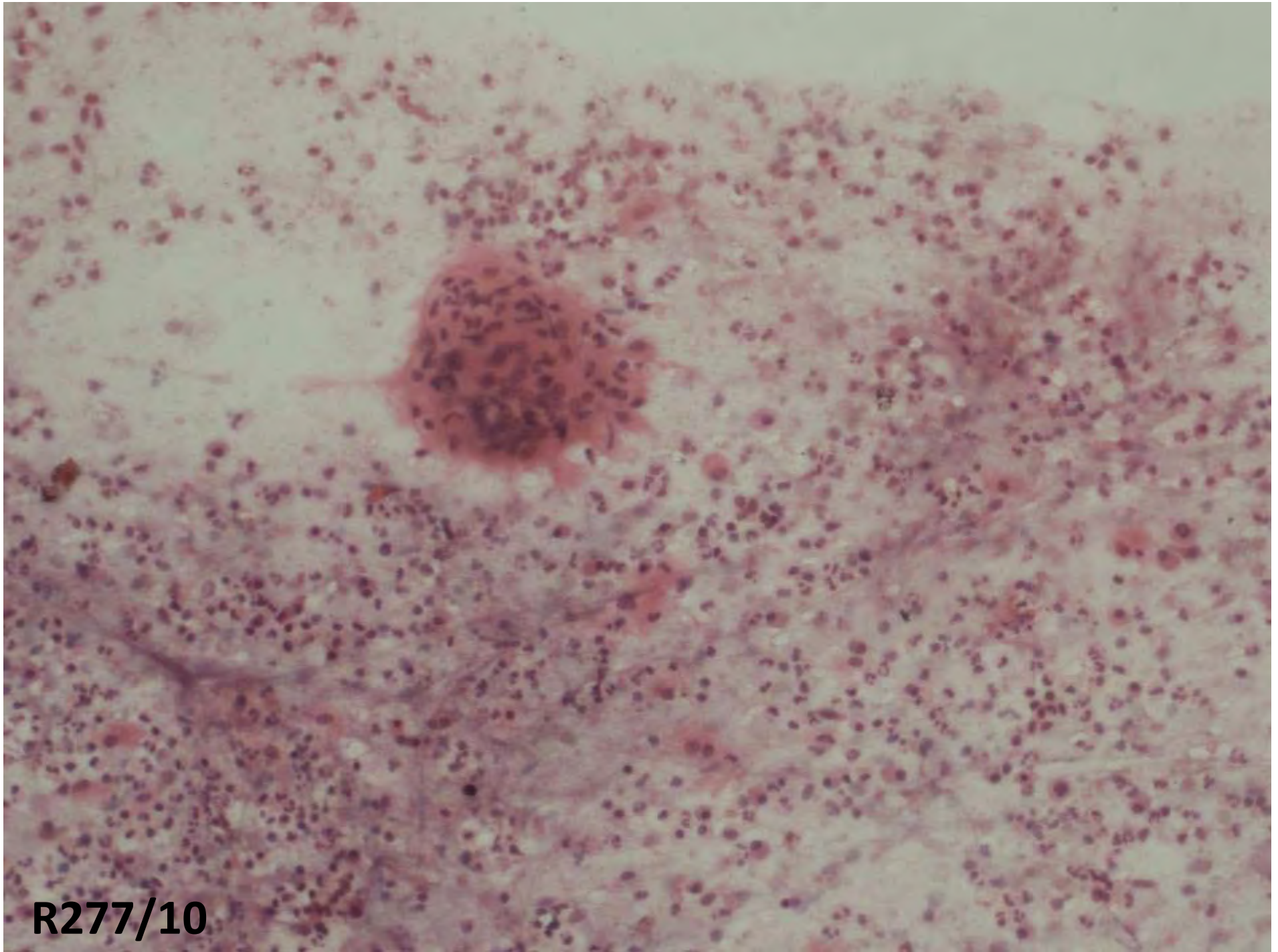


10Y587

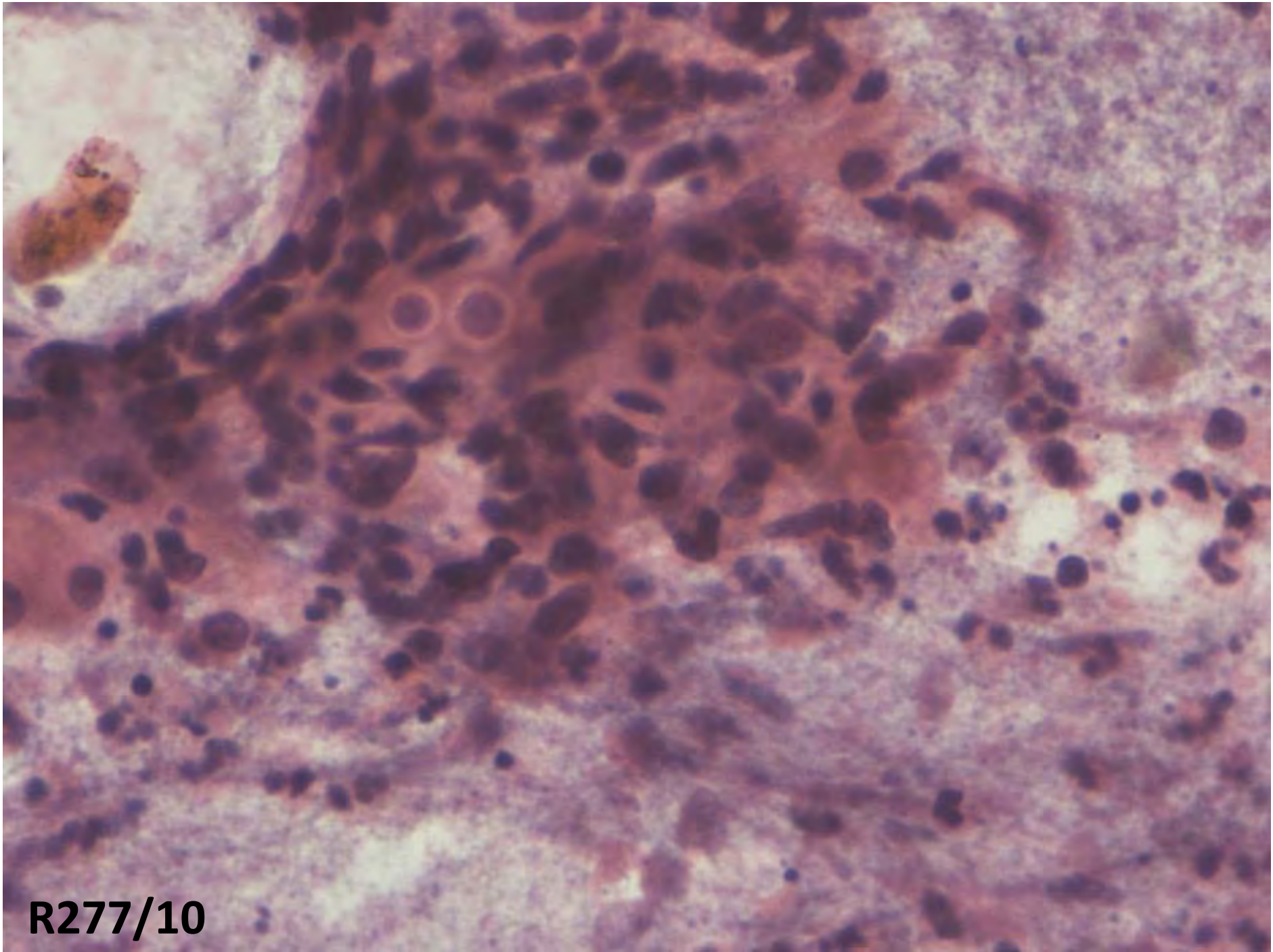
Case 2

- M/ 29yrs
- Fever, wt. loss: 2months
- Past history - Pleural effusion 7 yrs ago; had ATT
- Multiple subcutaneous nodules
- Left upper lobe mass.
- CT s/o left upper lobe mass, 4x5 cm, invading the Pleura.
- FNAC of lung mass and biopsy of shin nodule

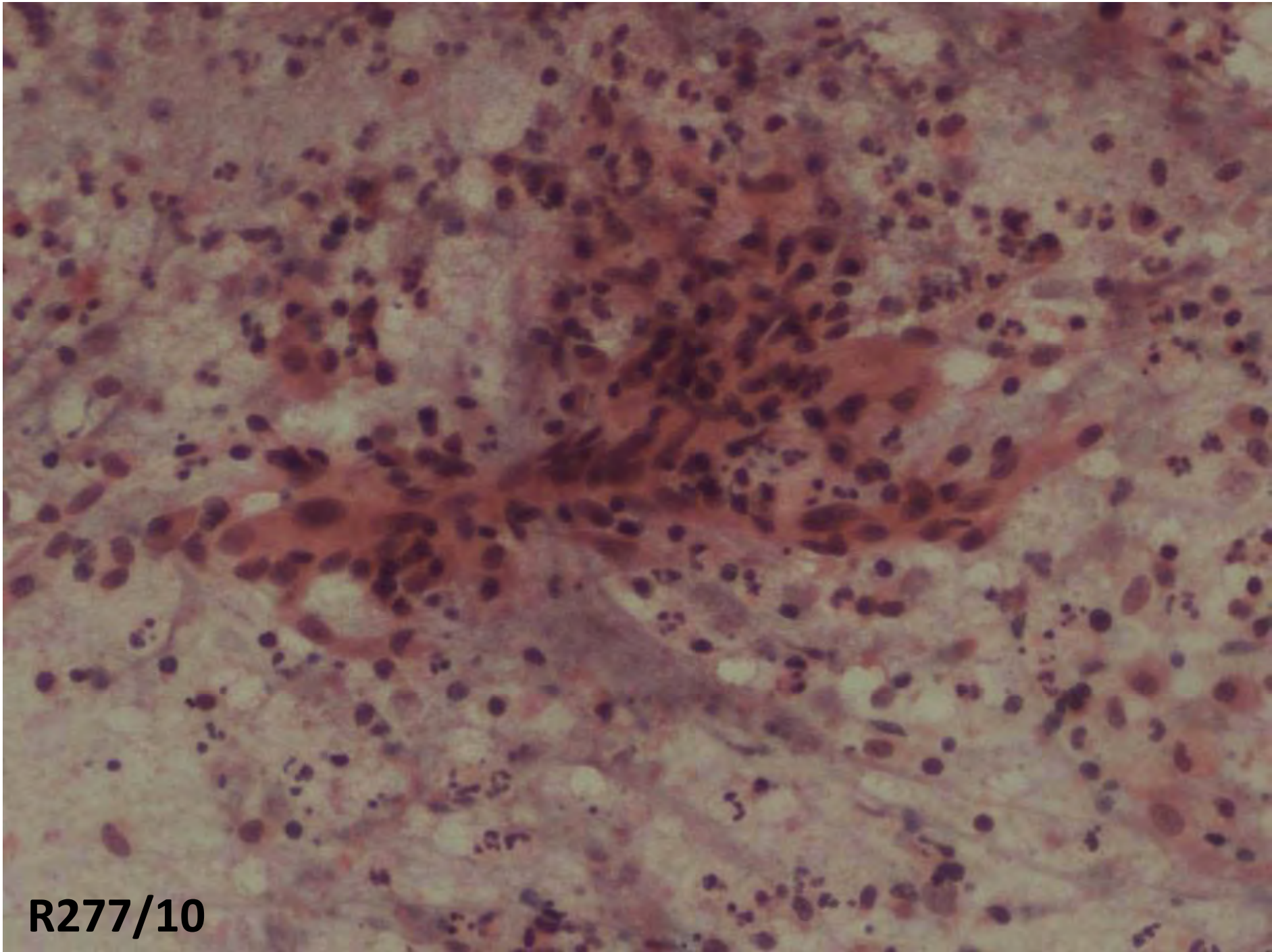




R277/10



R277/10



R277/10

Case 3

- M/ 4yrs
- Known case of swelling (R) foot
- Operated at the age of 1yr
- Recurrent swelling 7-8 months
- O/E: 4X4 cm, firm, fixed, lobulated swelling, medial malleolus, soft to firm with skin stretched over the malleolus
- No neurologic deficit
- No lymphadenopathy

9Y2770

KOUSIK

[AF]

RT.FOOT

5055

8/27/2009

2429

M

12 - 9

TR 600.0 ms

...

[R]

[L]

SP: -62.2mm

ST: 4.0mm

256x256

C432

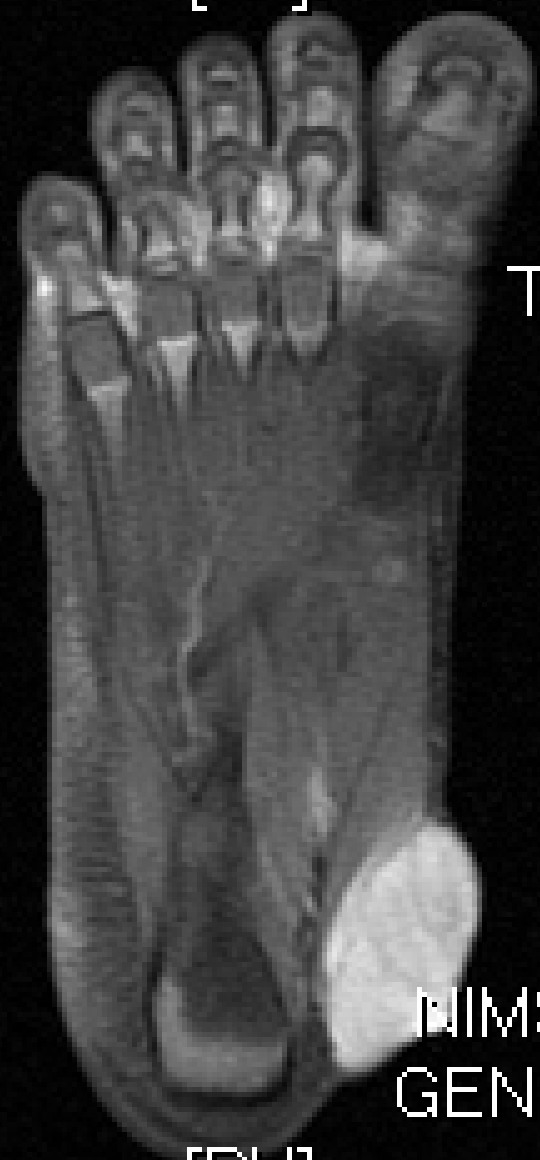W864

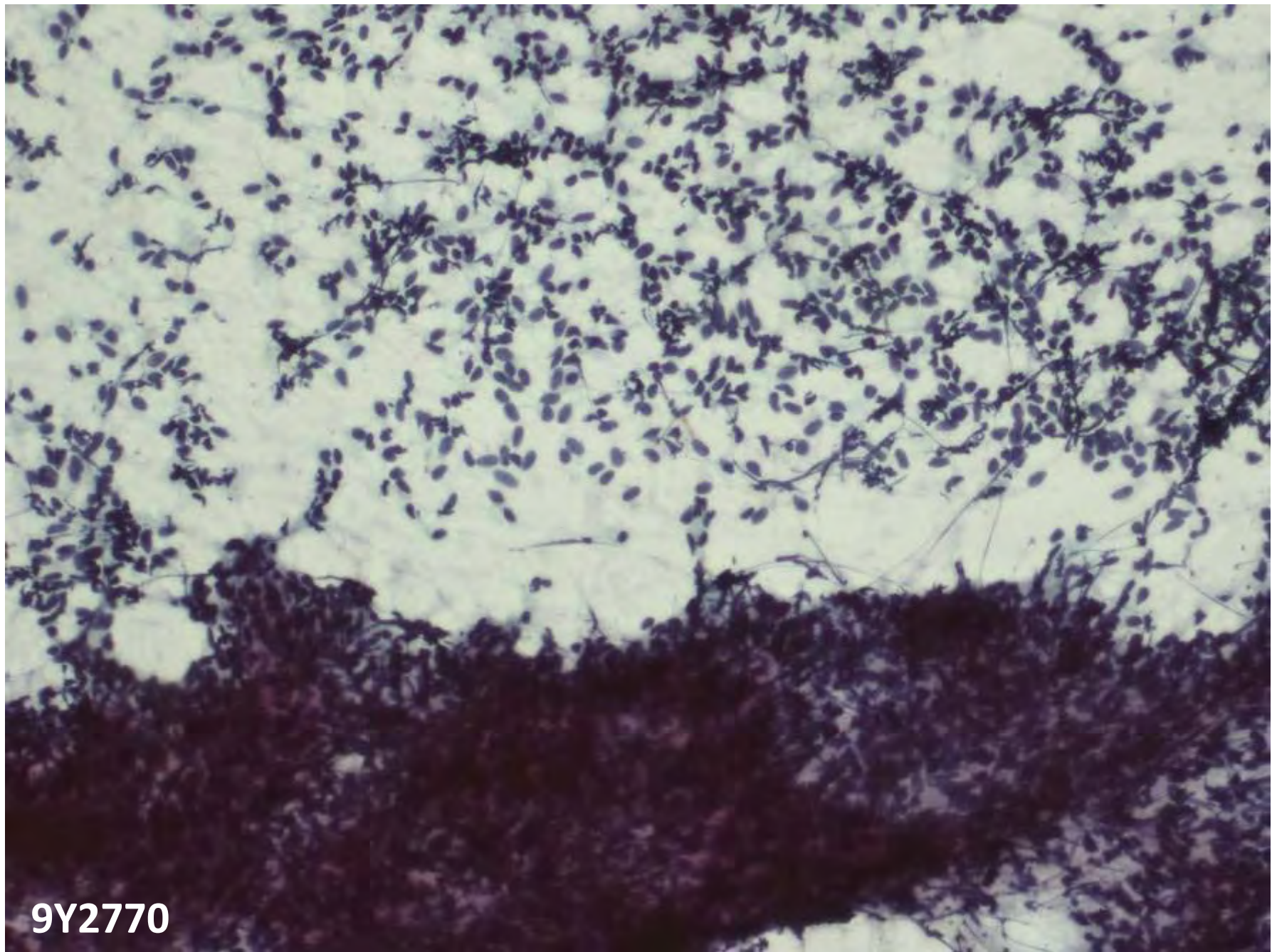
NIMS HYDER...

GENESIS_SIG...

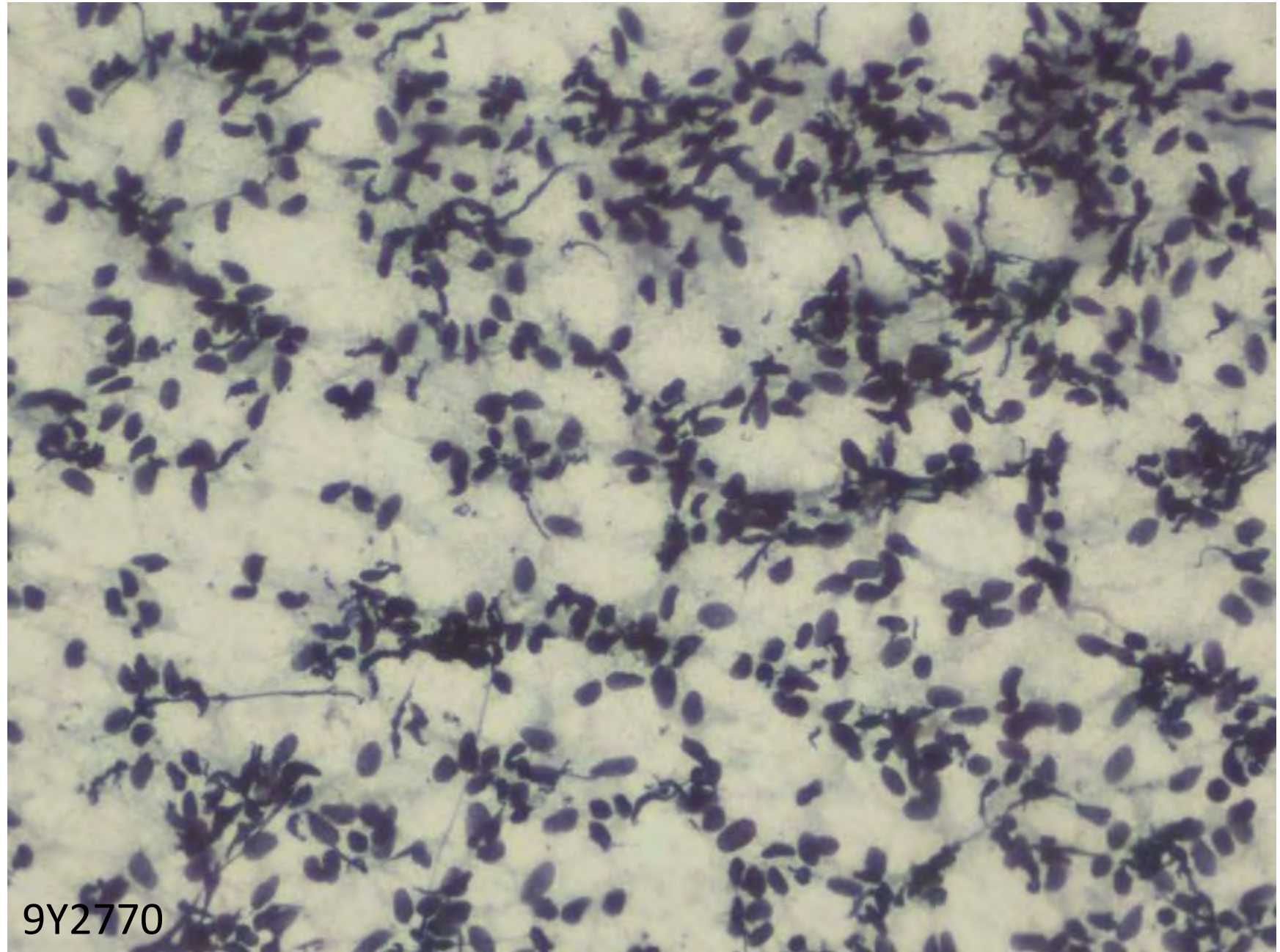
[PH]

9Y2770

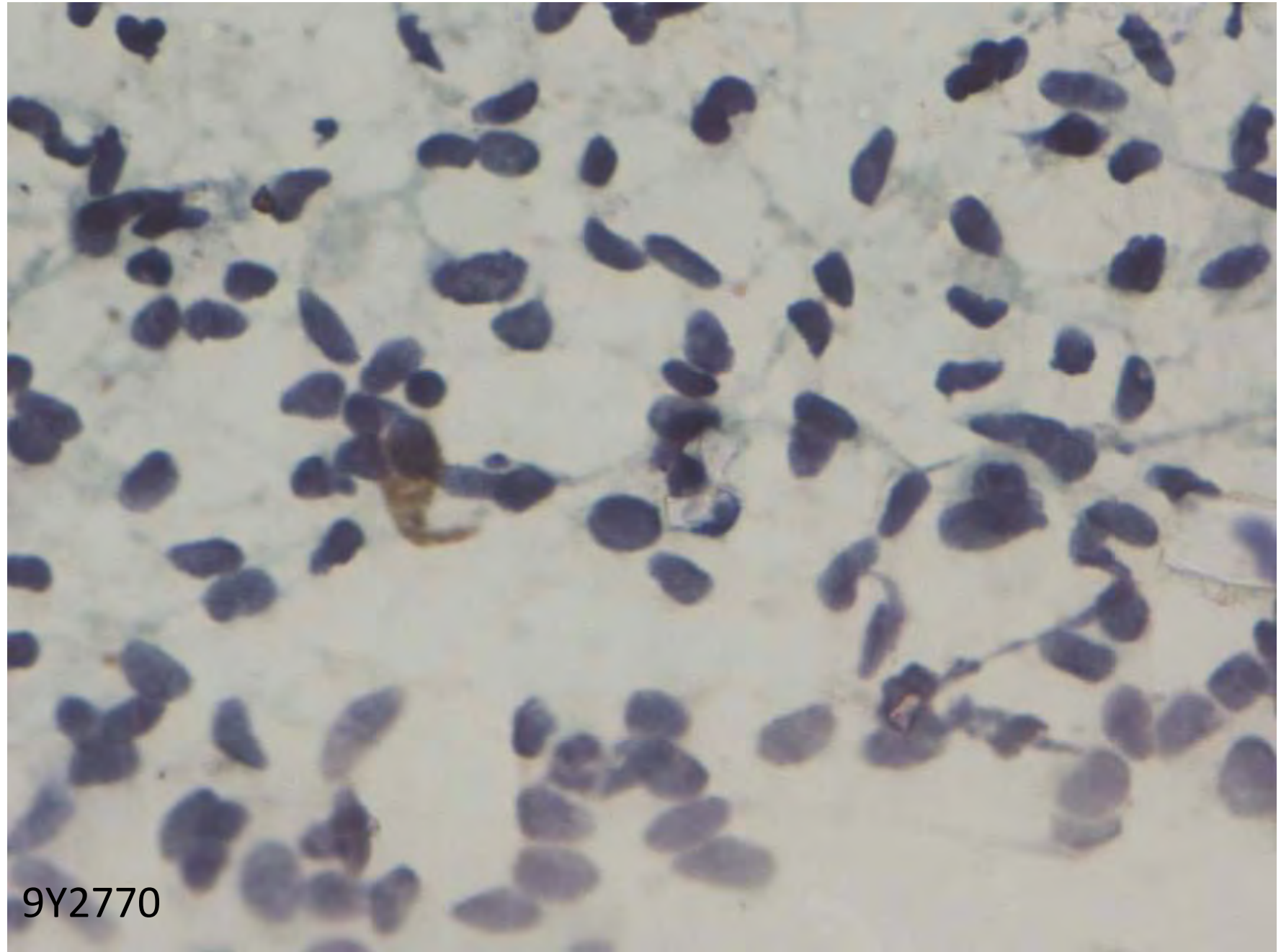




9Y2770



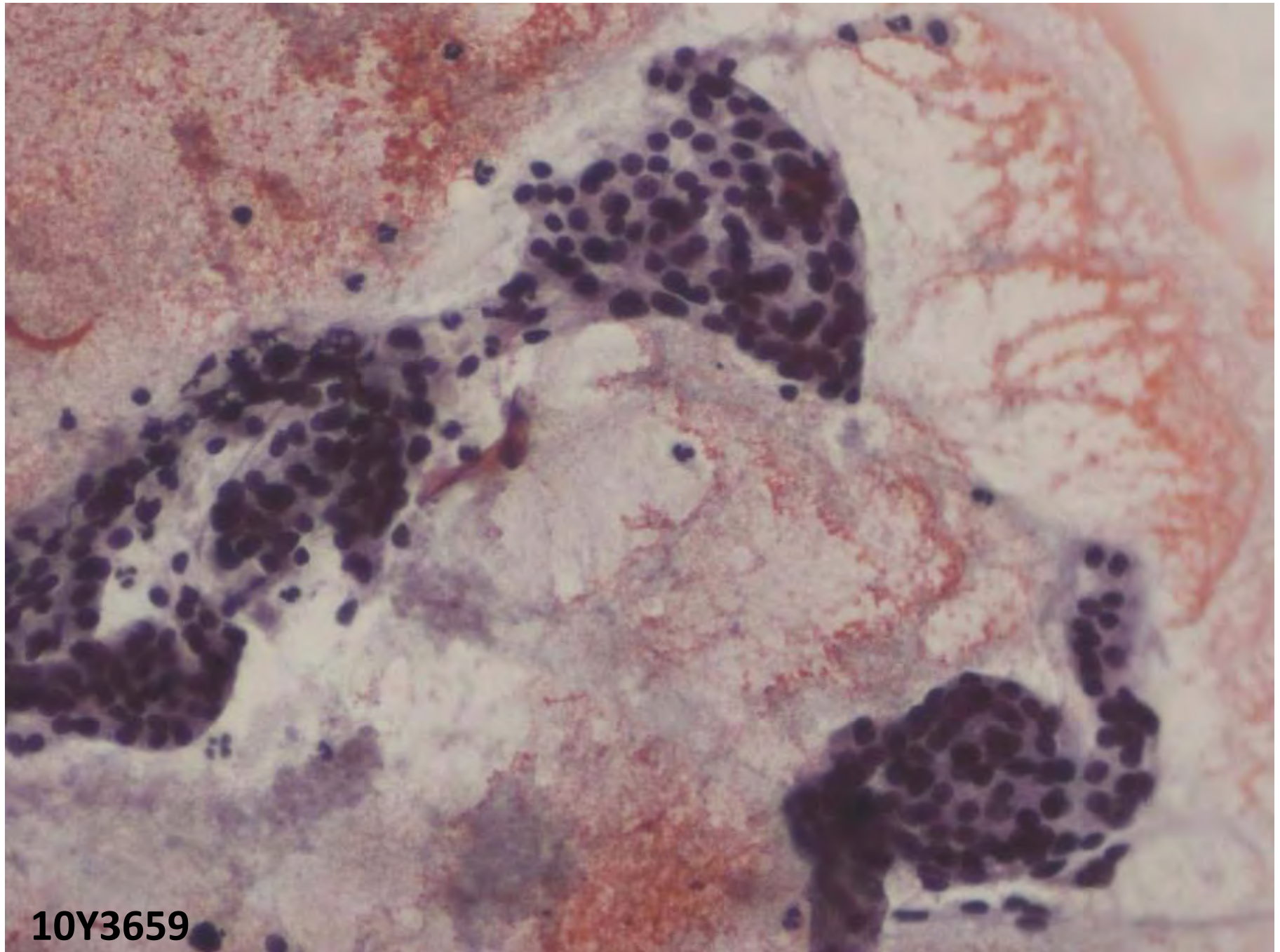
9Y2770



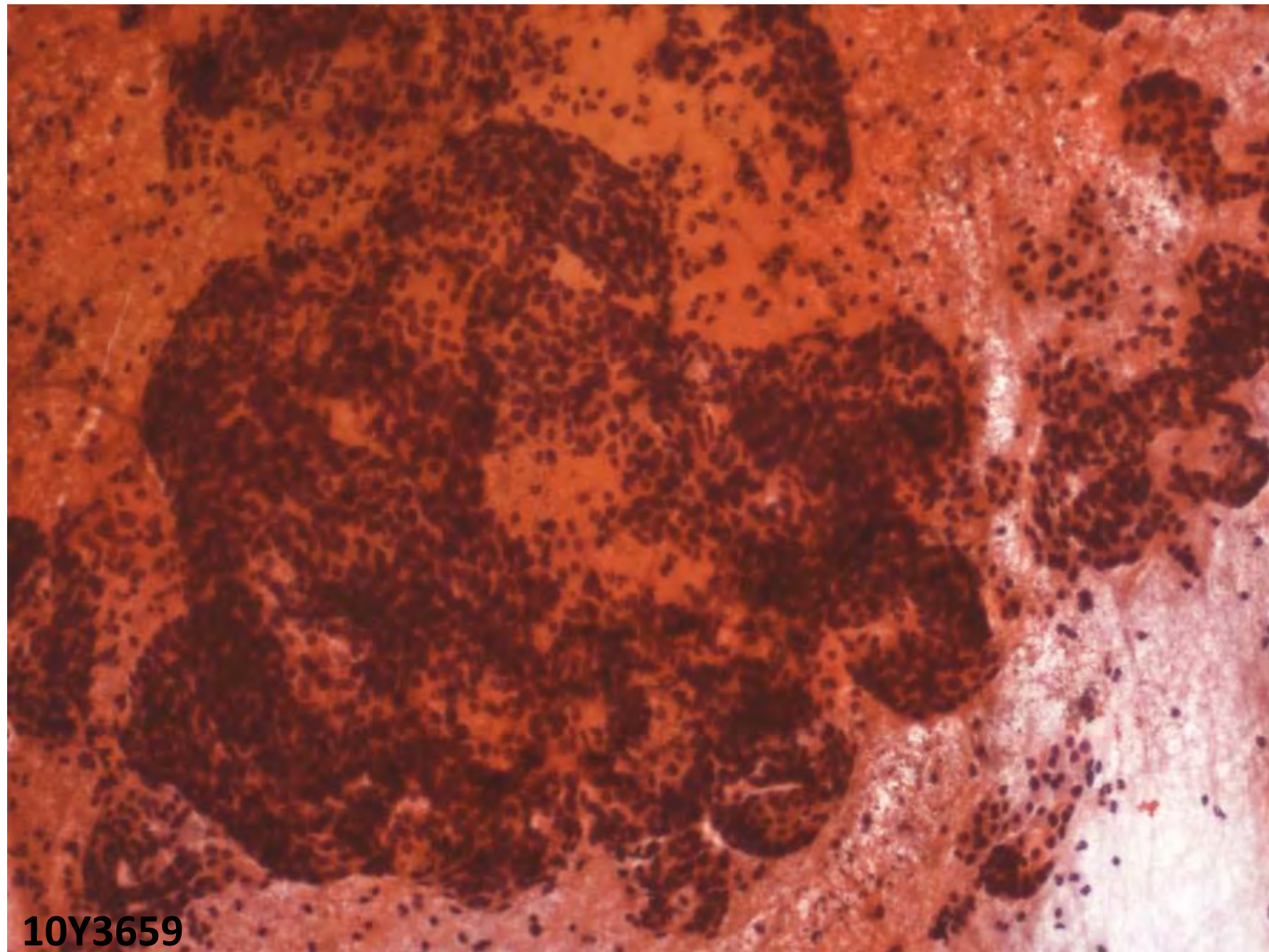
9Y2770

Case 4

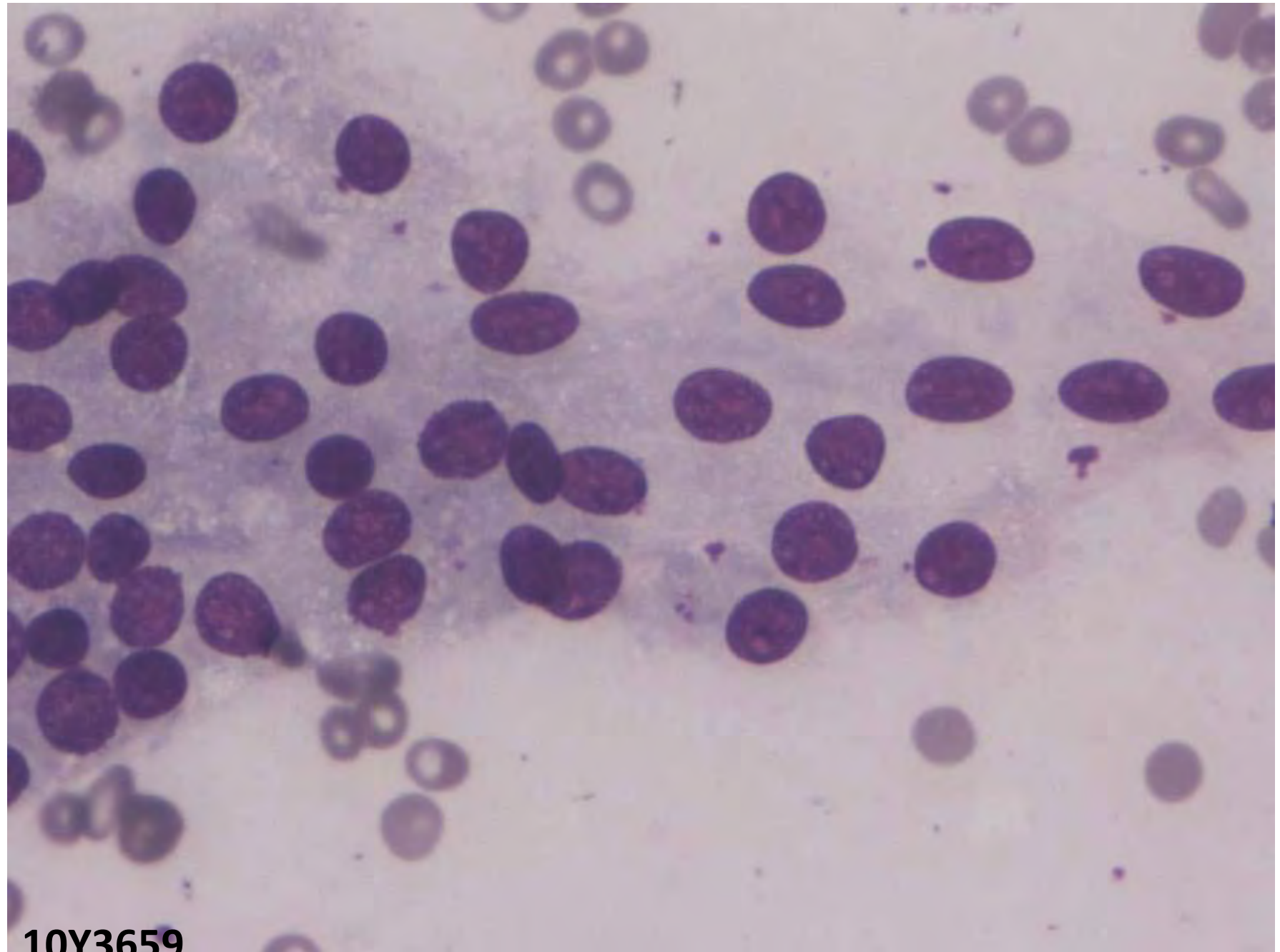
- 44/F
- C/o renal failure
- Nodule in thyroid
- Radionuclide scan: cold nodule in thyroid
- USG: Large hypoechoic SOL (R) lobe of thyroid with cystic change



10Y3659



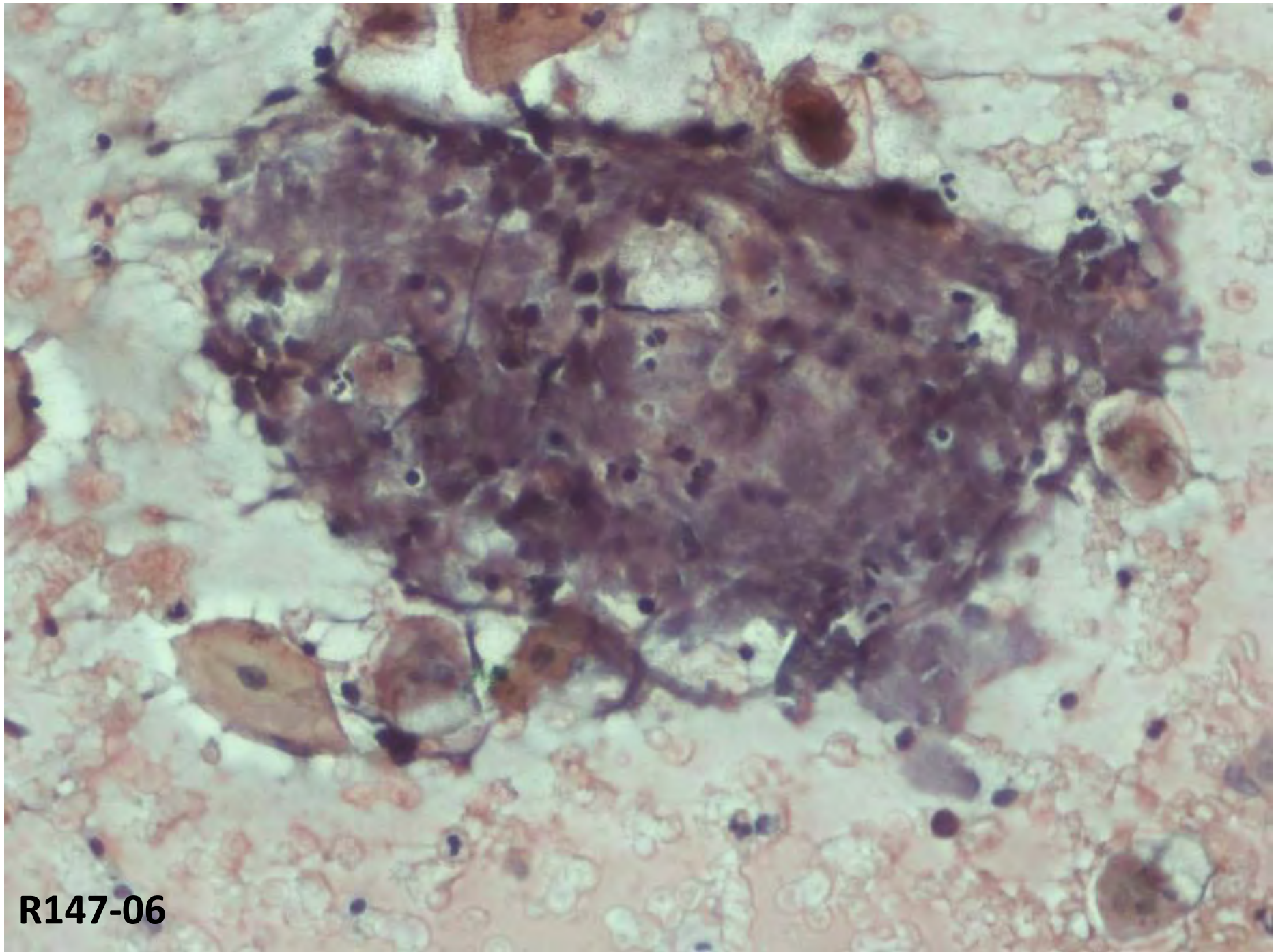
10Y3659



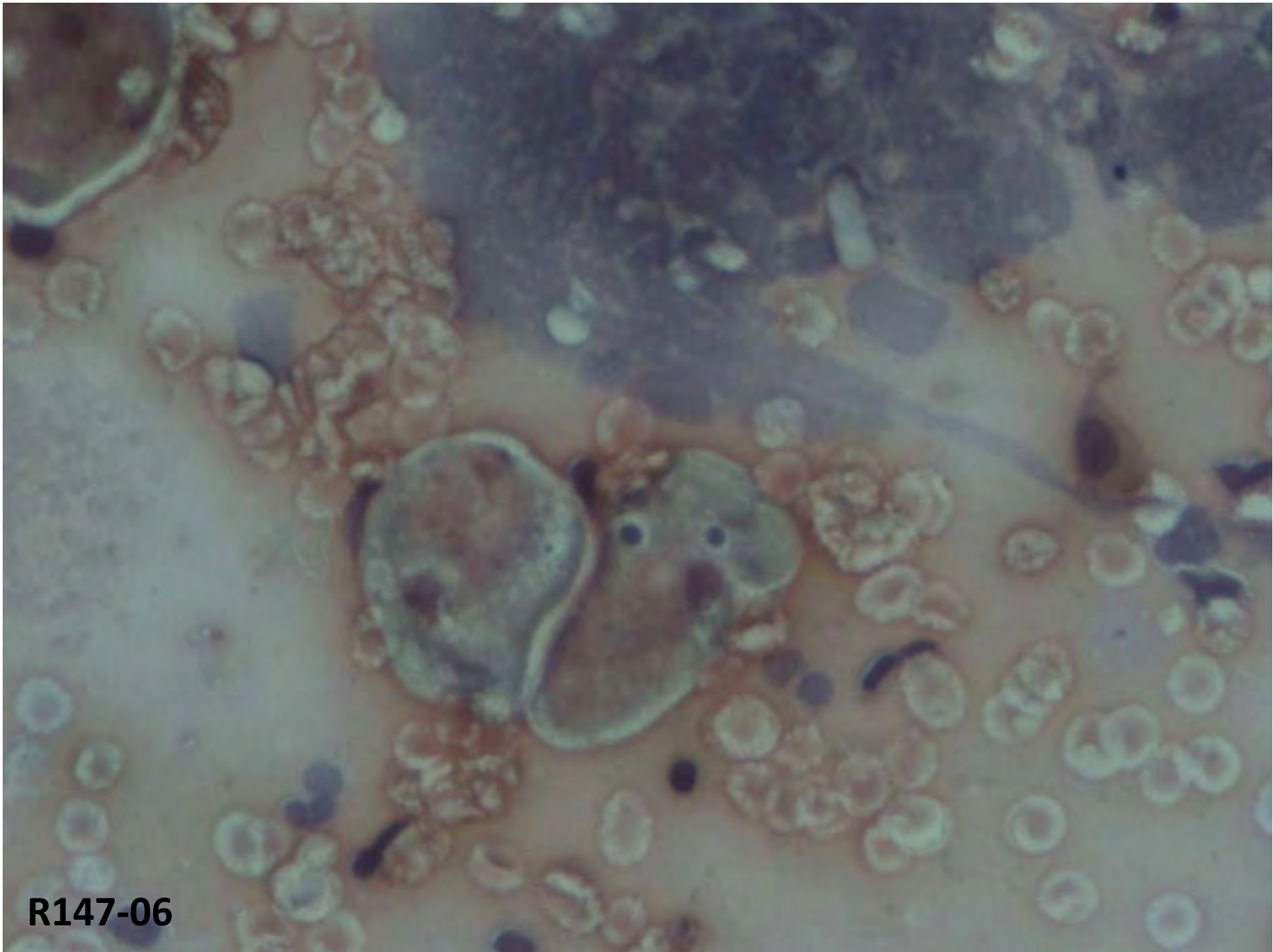
10Y3659

Case 5

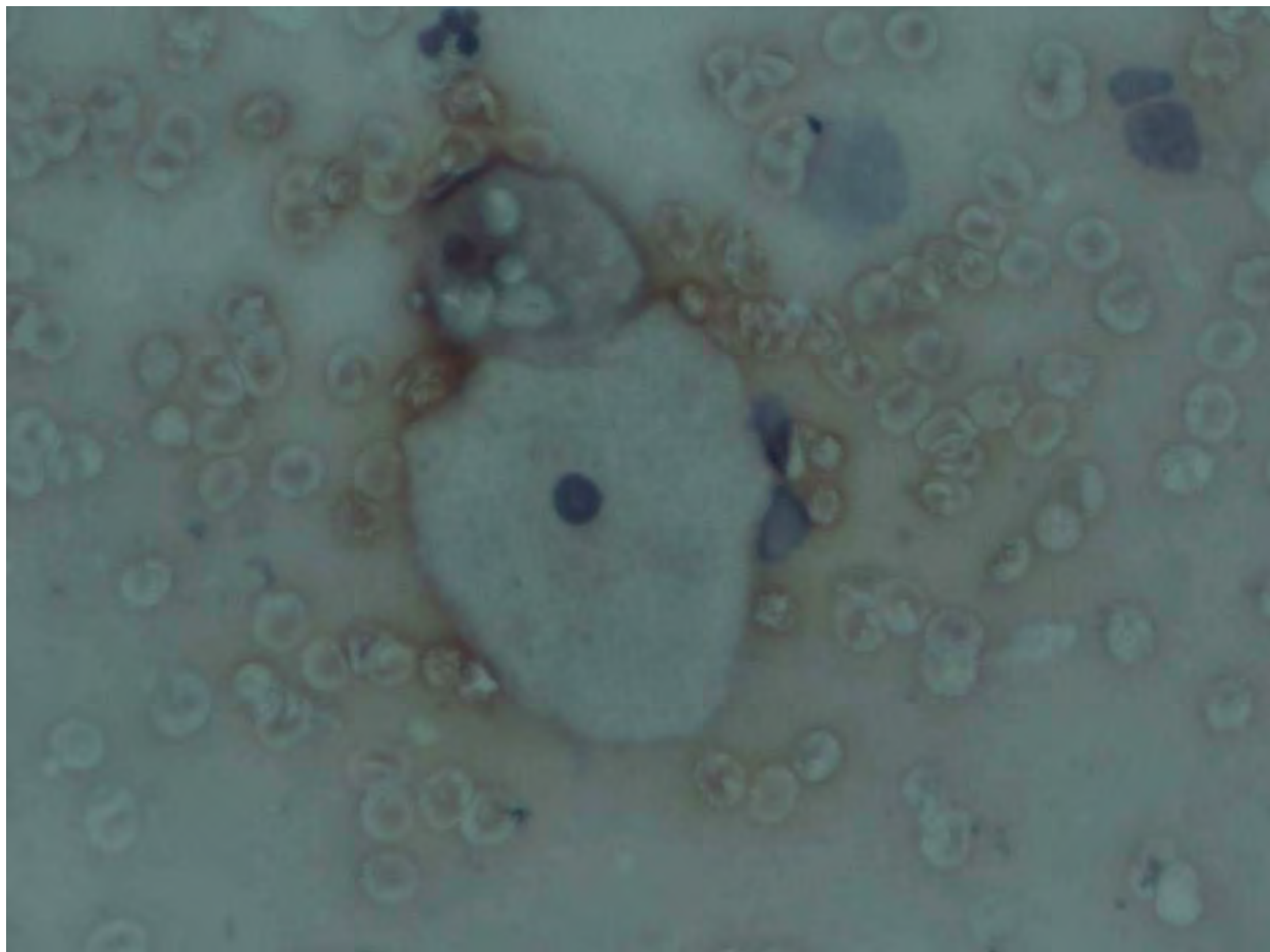
- 58/F
- Brownish discharge per vagina: 10days
- No frank bleeding
- Menopause: 10yrs back
- Multipara, no DM, not obese
- P/S cauliflower like growth in vagina ? Arising from cervix
- Smears from growth and biopsy



R147-06

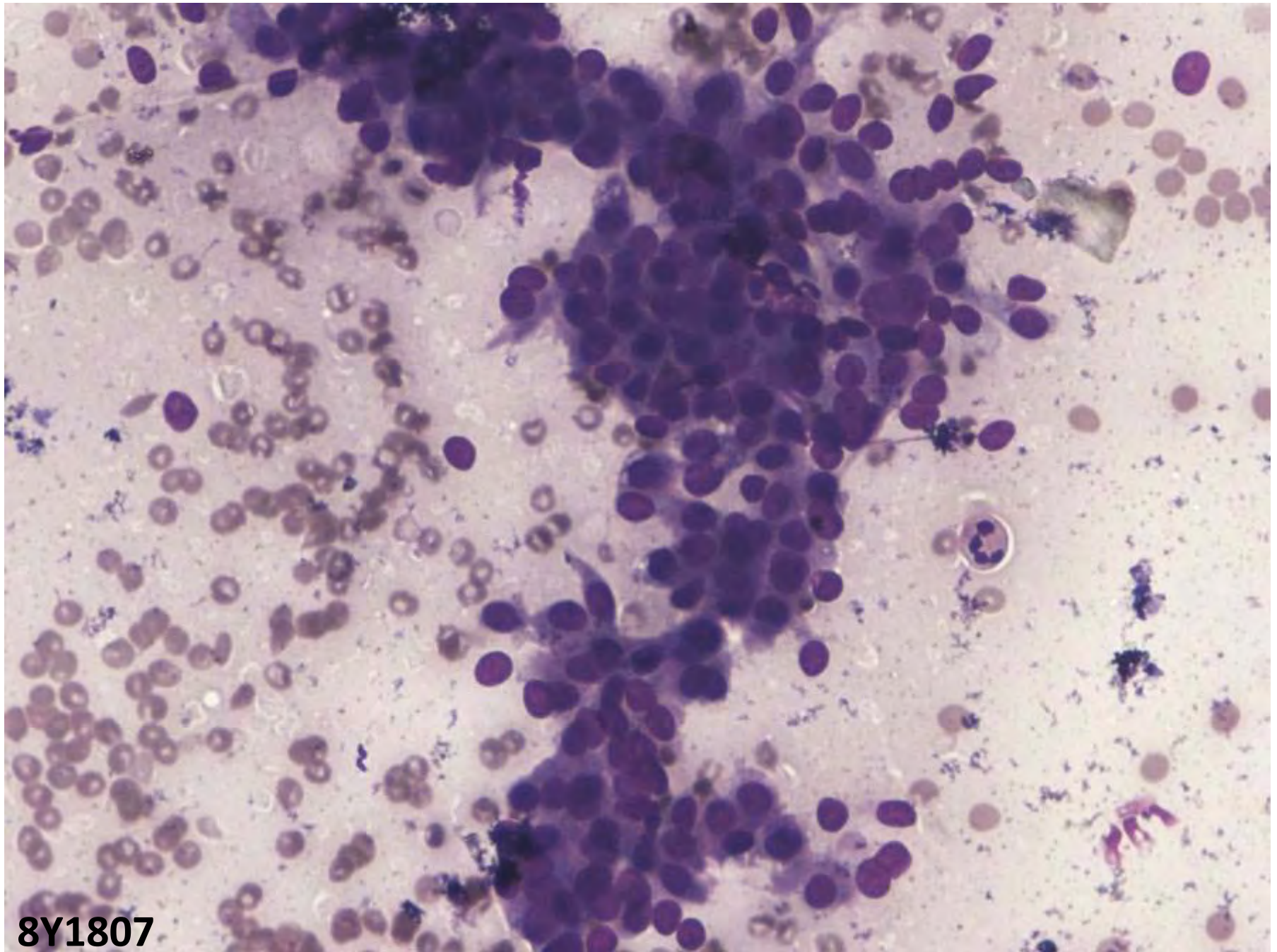


R147-06

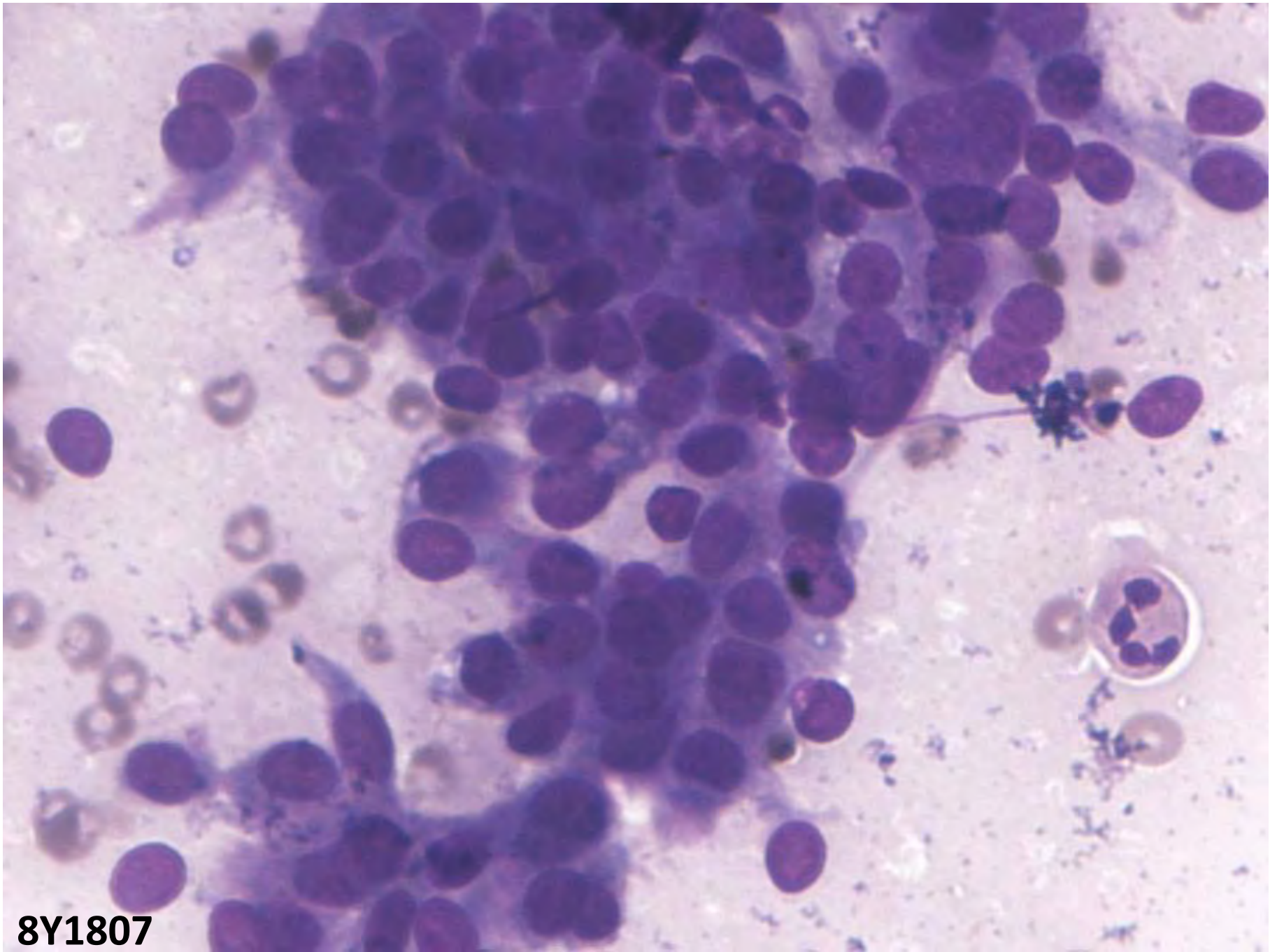


Case 6

- 15/F
- Swelling (R) parotid: 6yrs
- Increasing in size
- 3 X 3cm, firm, mobile
- No lymphadenopathy



8Y1807

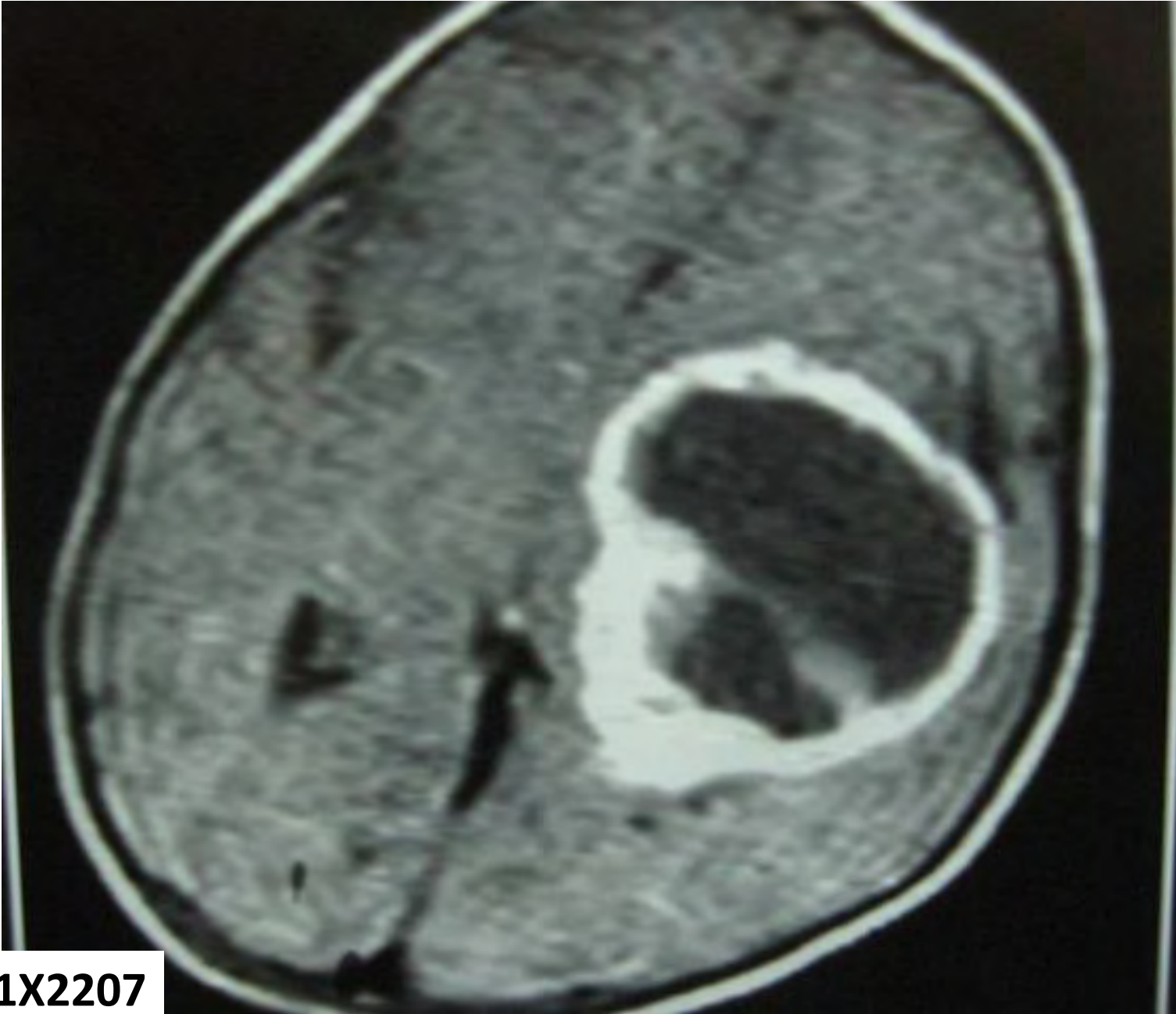


8Y1807

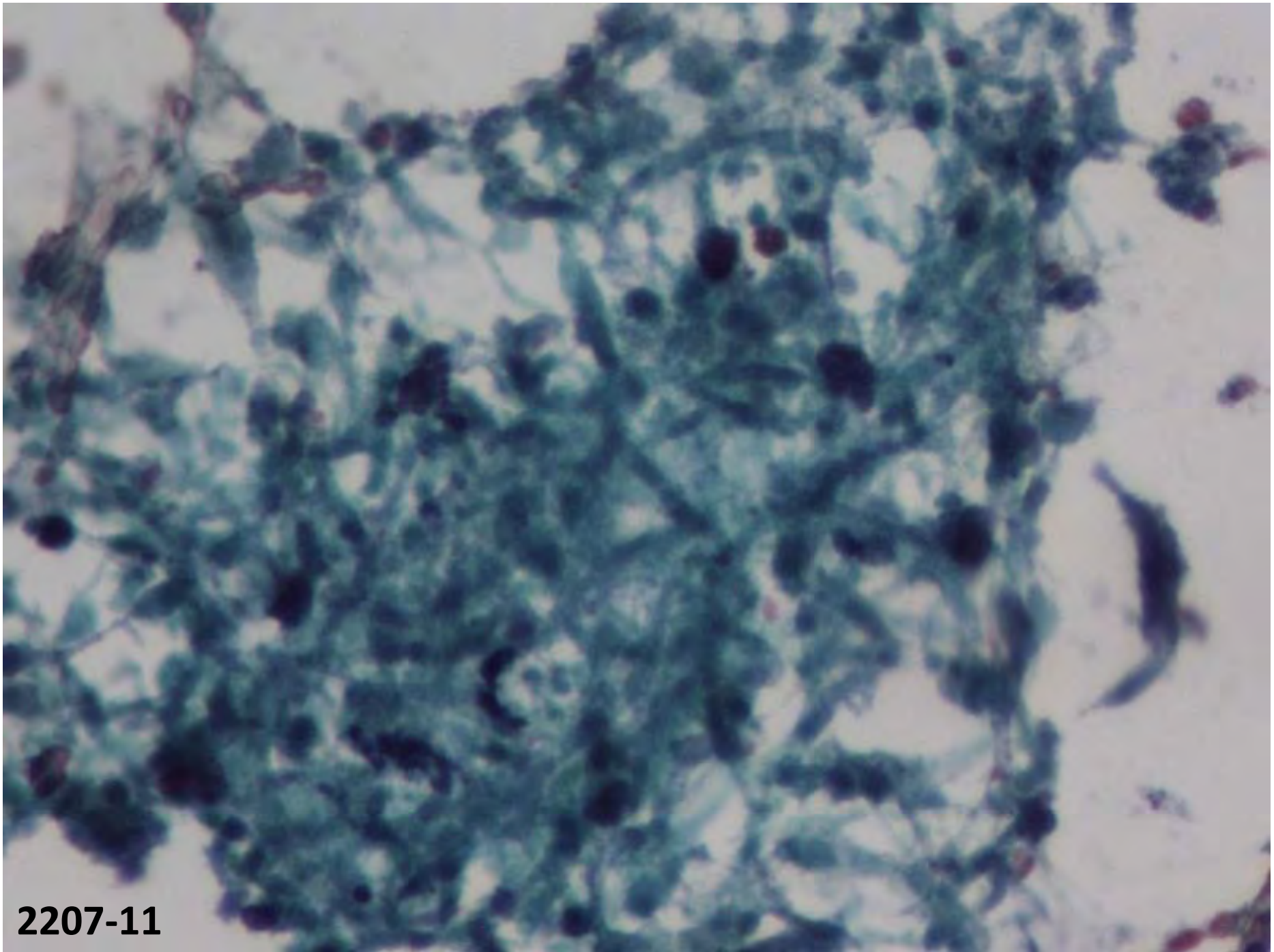
Case 7

- 1 year old male
- H/O weakness Rt. Upper and lower limbs
- No h/o seizures, vomiting
- O/E: Rt. Hemiparesis
- MRI: Lt. temporal ring enhancing lesion
- Cyst fluid for cytology

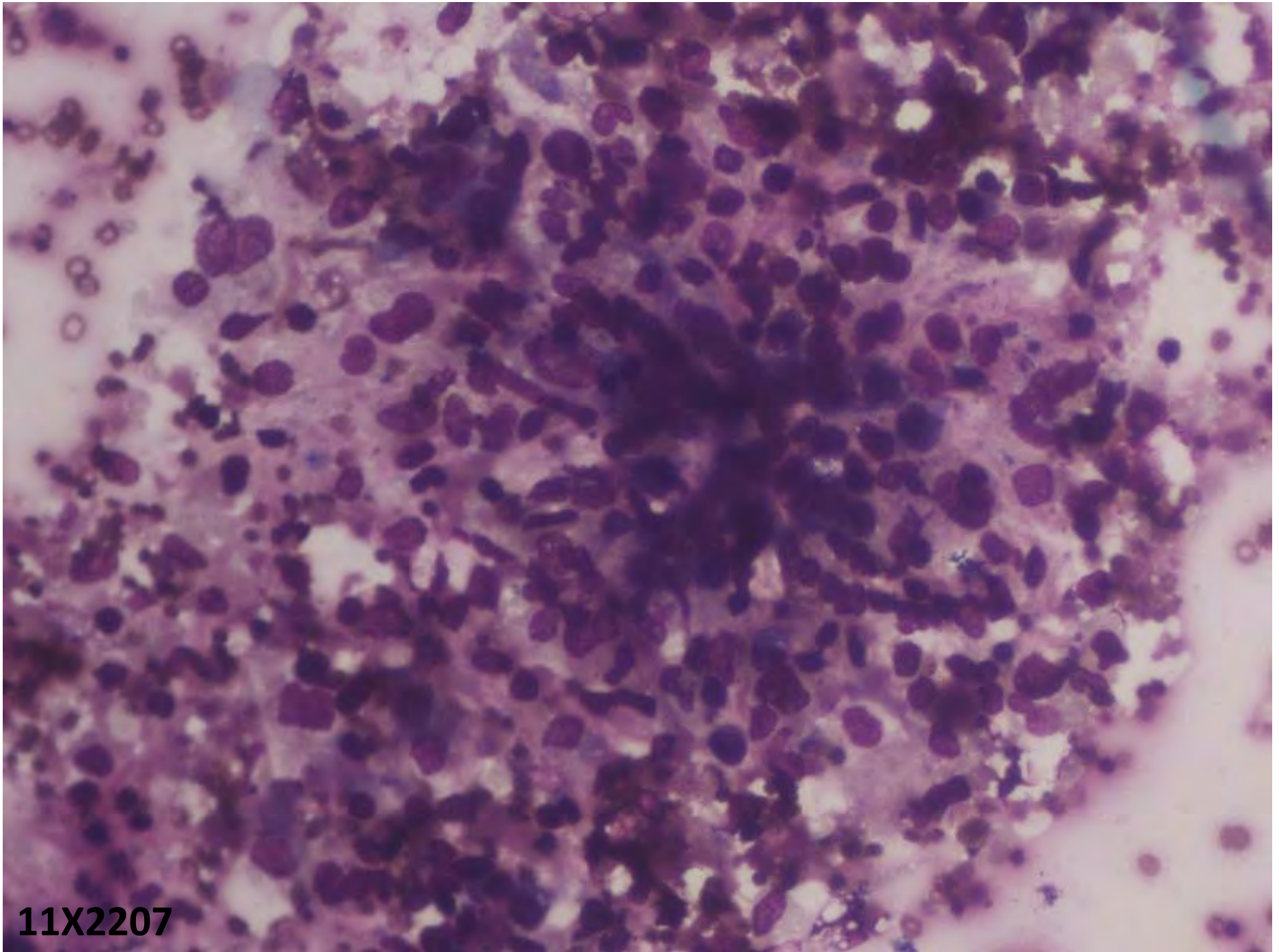
11X2207



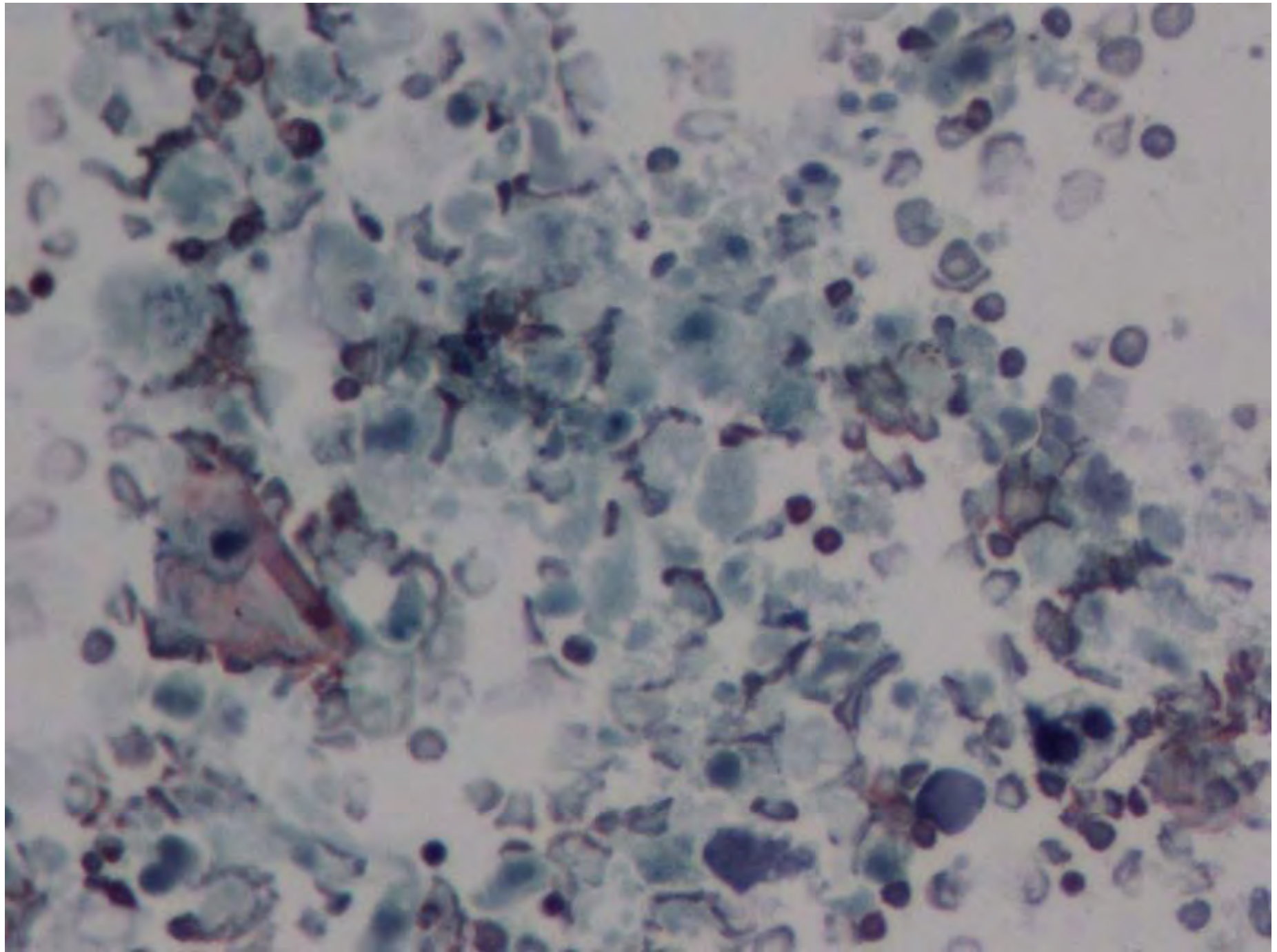
11X2207



2207-11

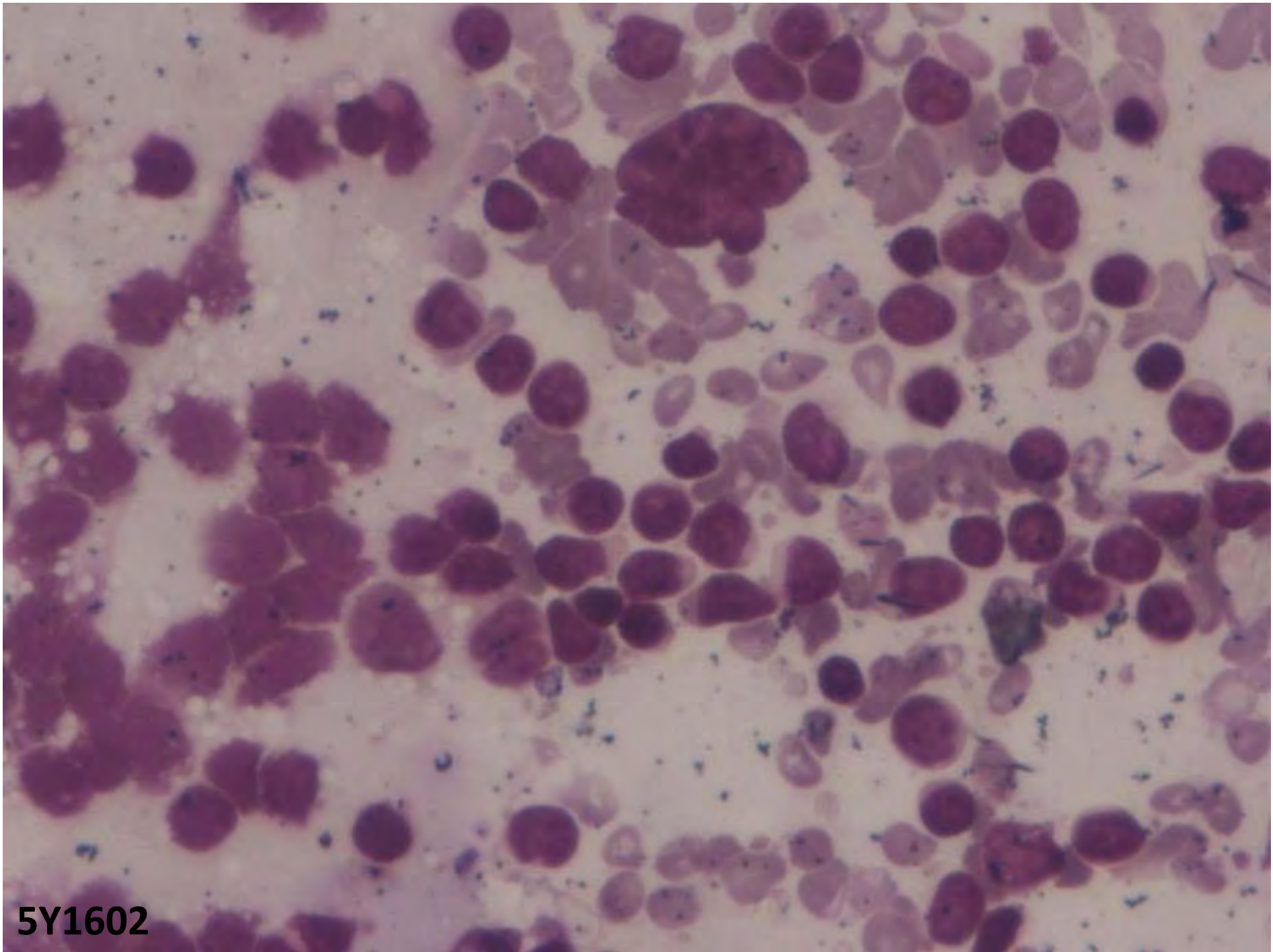


11X2207

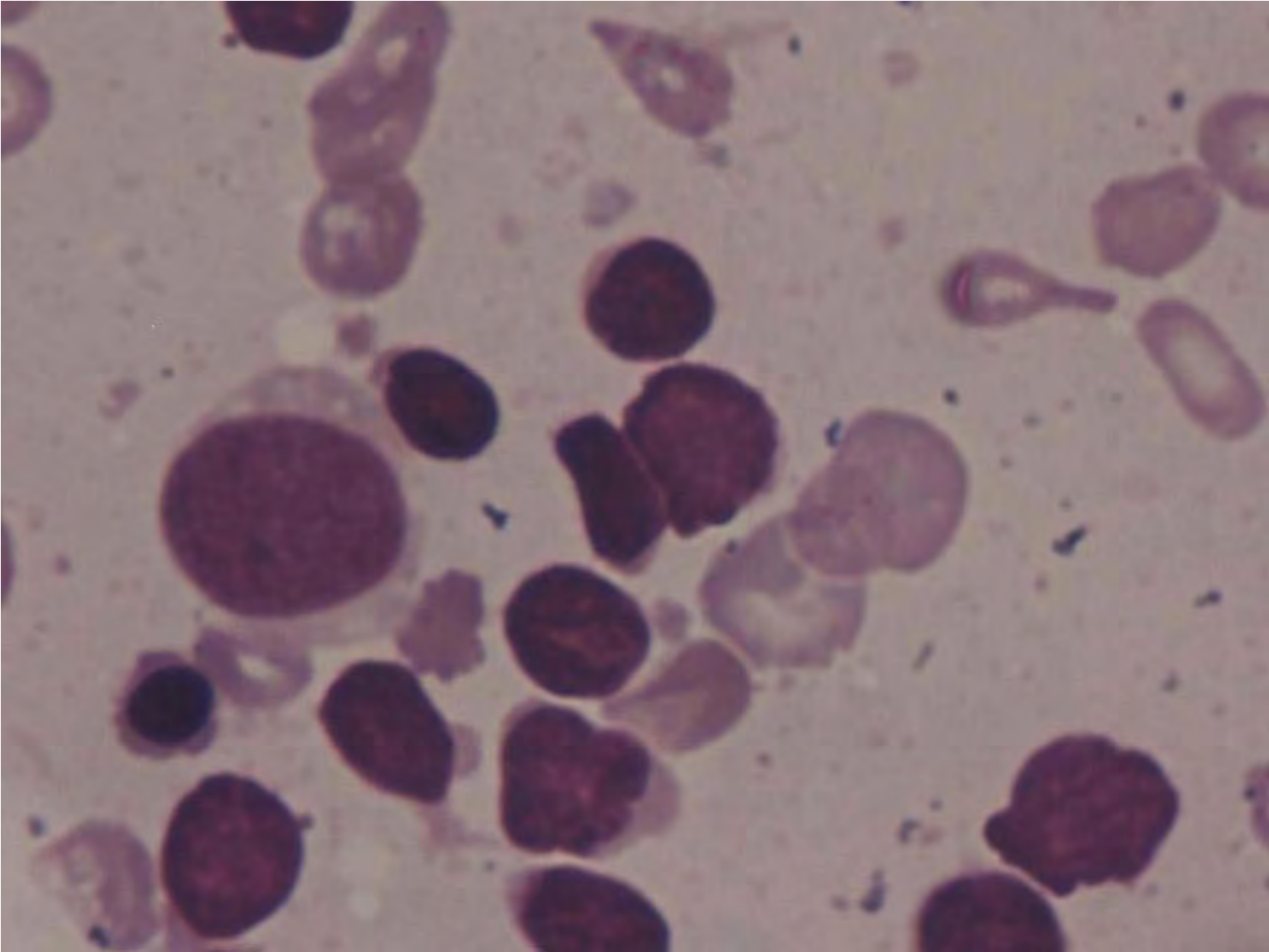


Case 8

- Male aged 55yrs
- Weakness, pallor: since childhood
- Transfused 3 units of blood
- Lymphadenopathy: axillary, cervical
- Gross Splenomegaly
- ? NHL
- FNAC: Lymph node

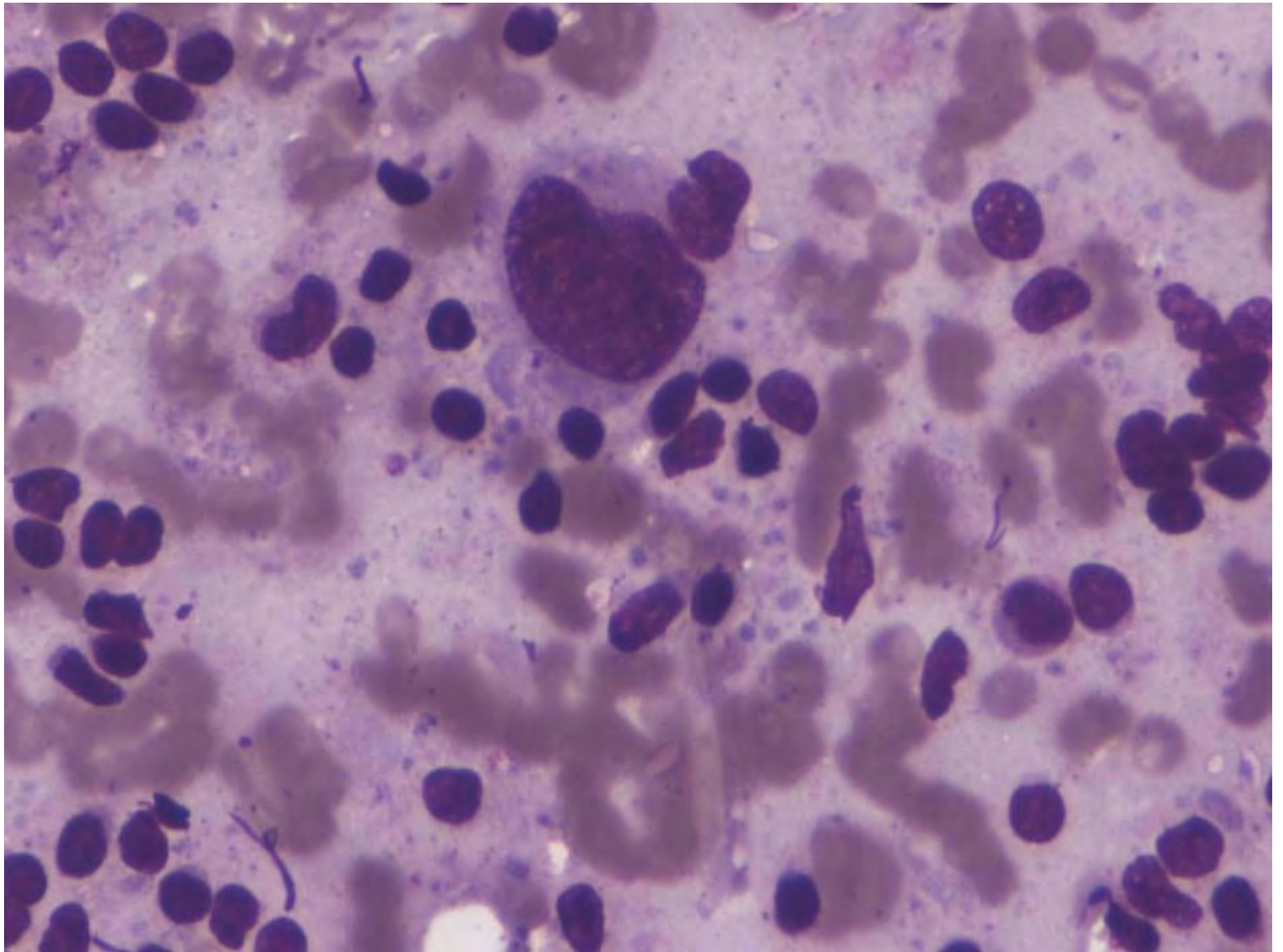


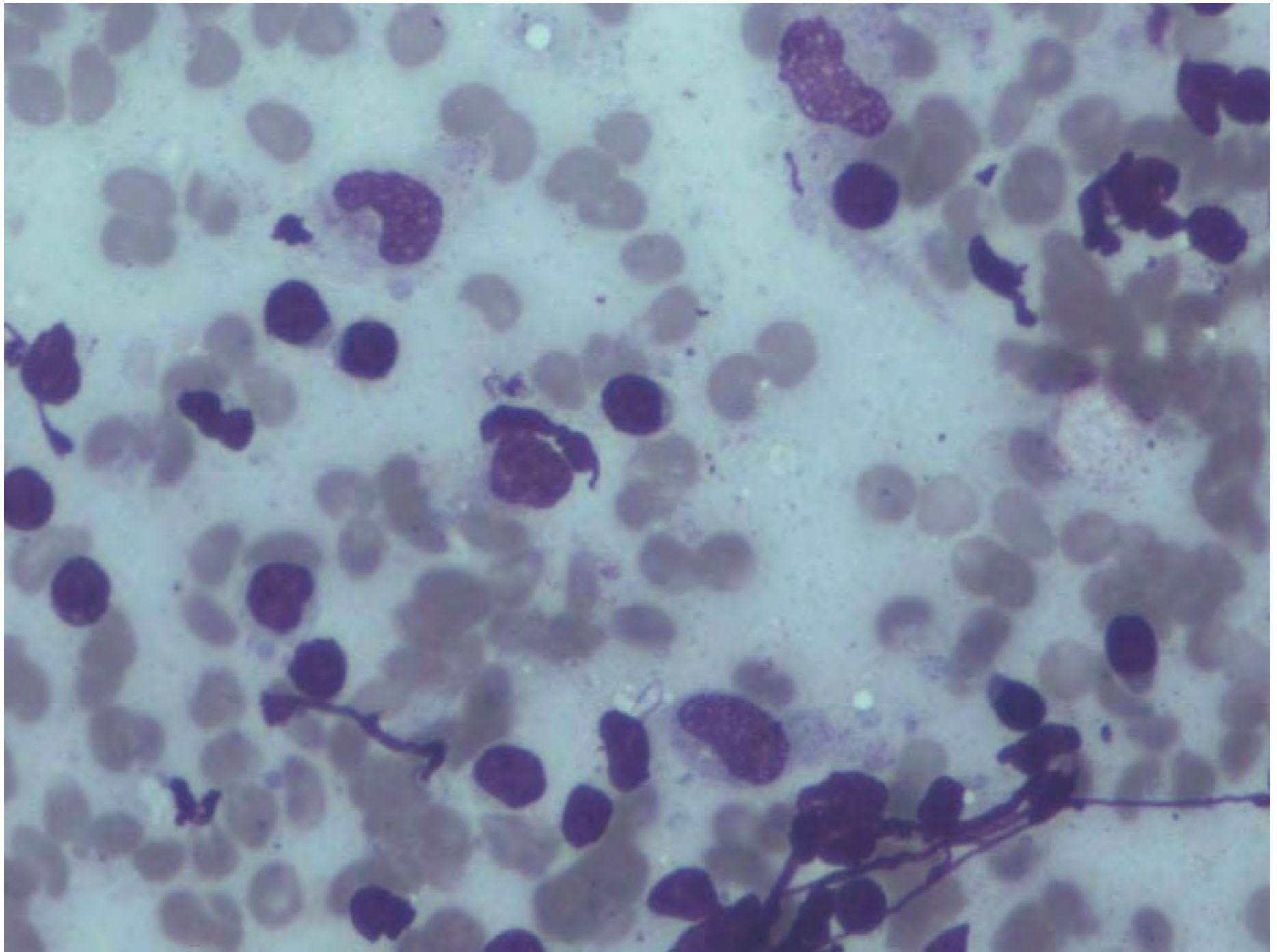
5Y1602

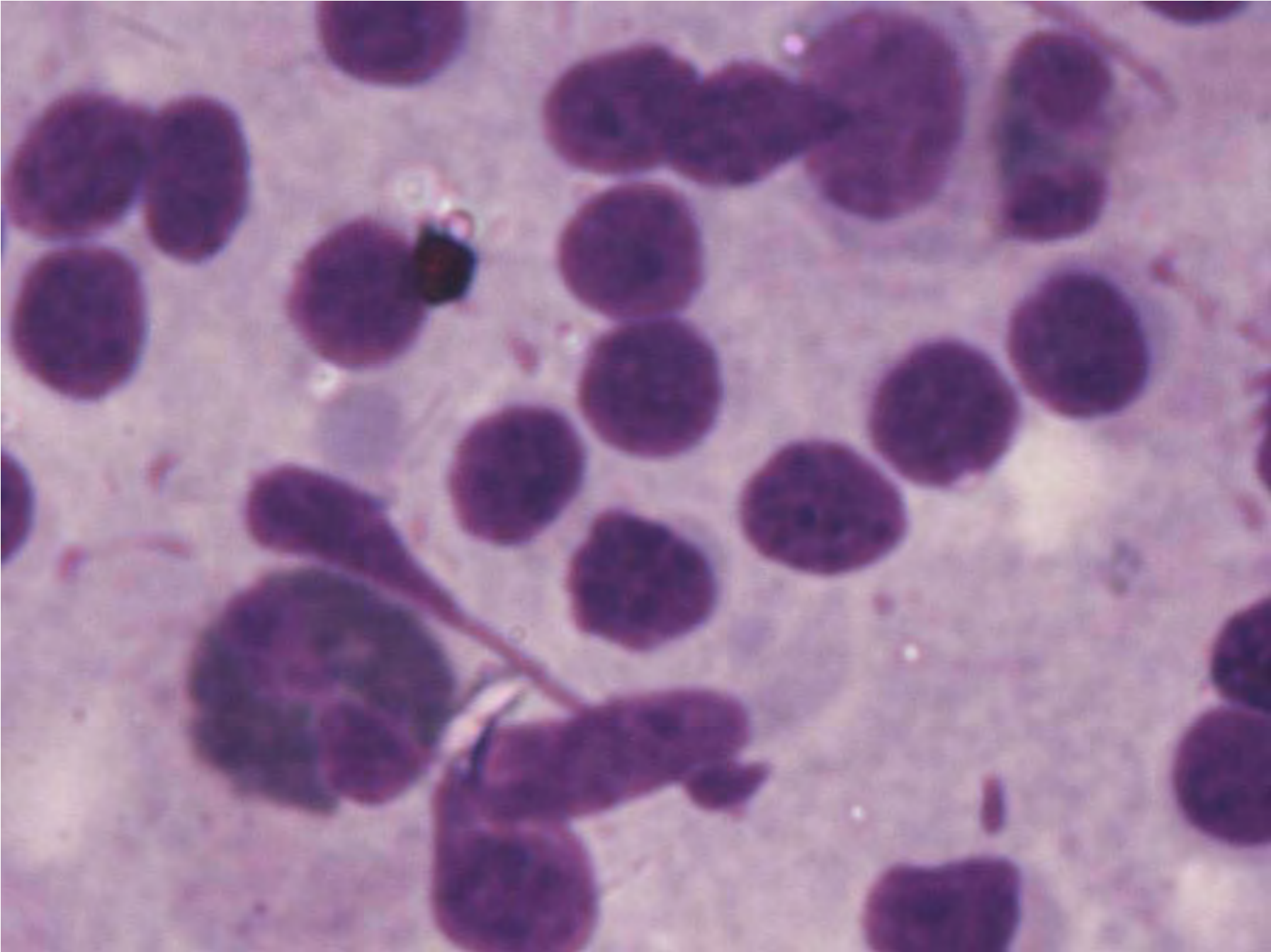


Case 9

- M/ 40yrs
- CML on Imatinib: 1yr 3 months
- Bilateral neck nodes: 1month
- No fever, LOA, LOW
- Cough: Productive +
- O/E: well preserved
- Clinical possibilities: EMCT, Tuberculosis
- FNAC: Lymph node

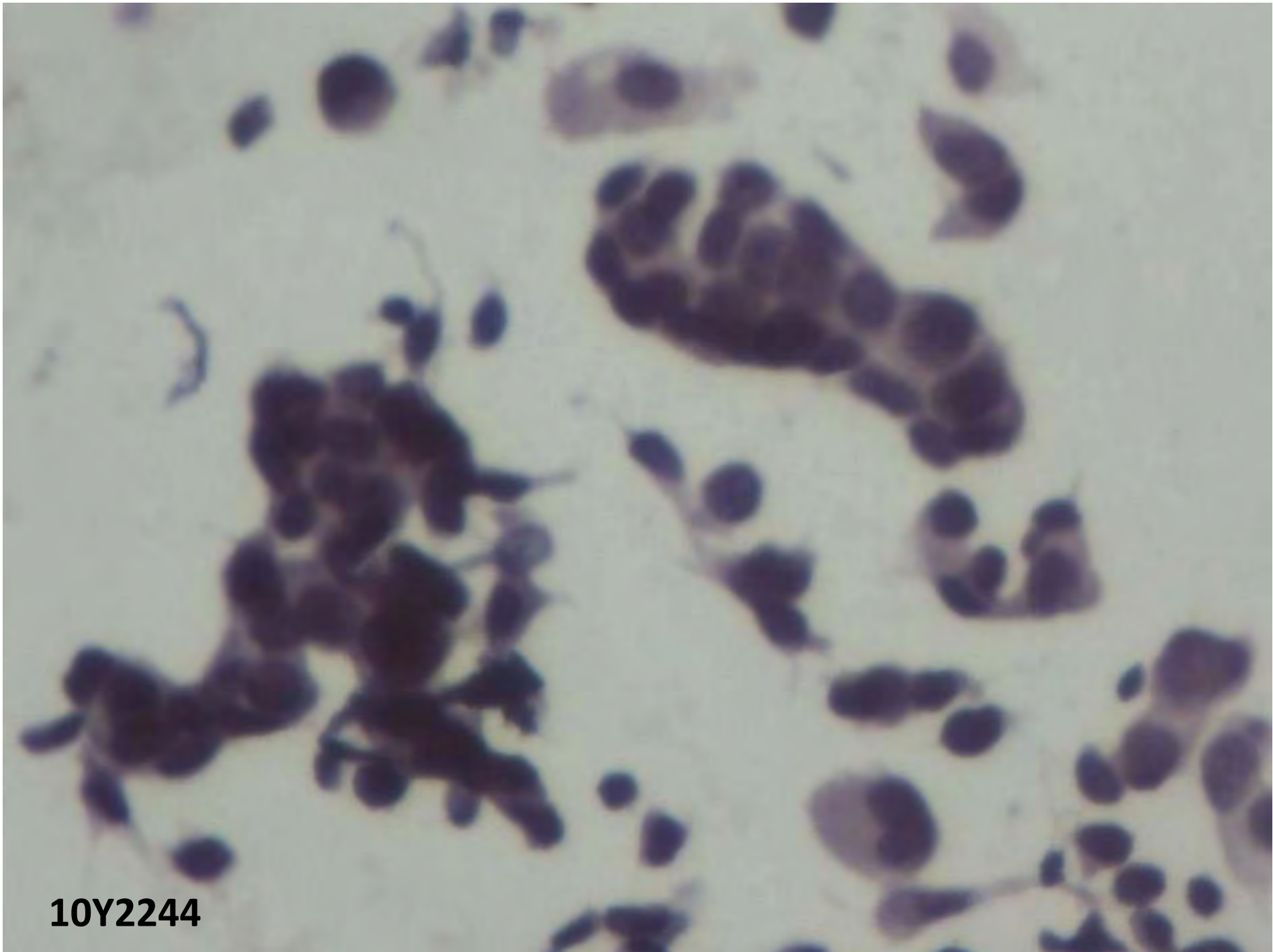




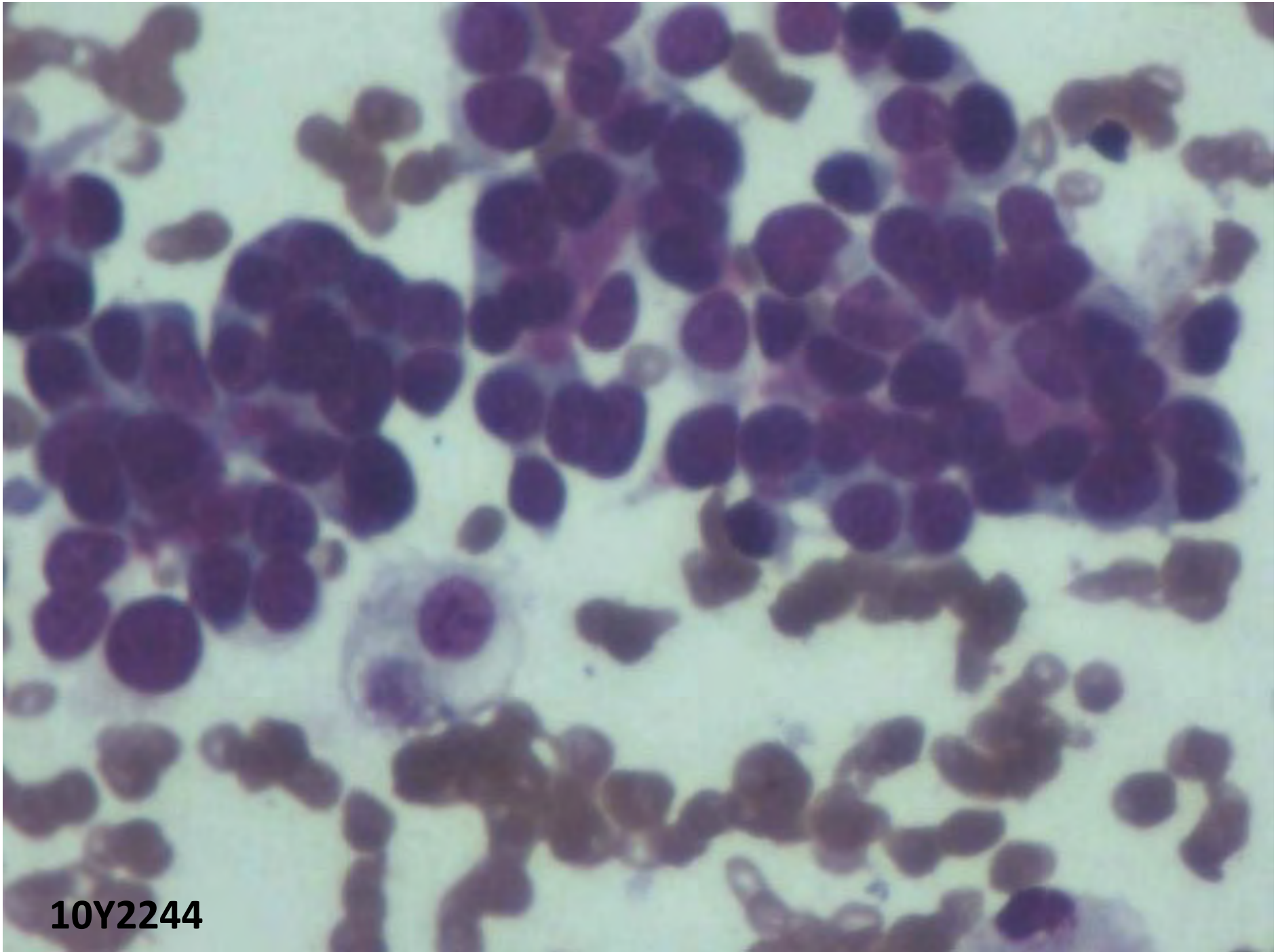


Case 10

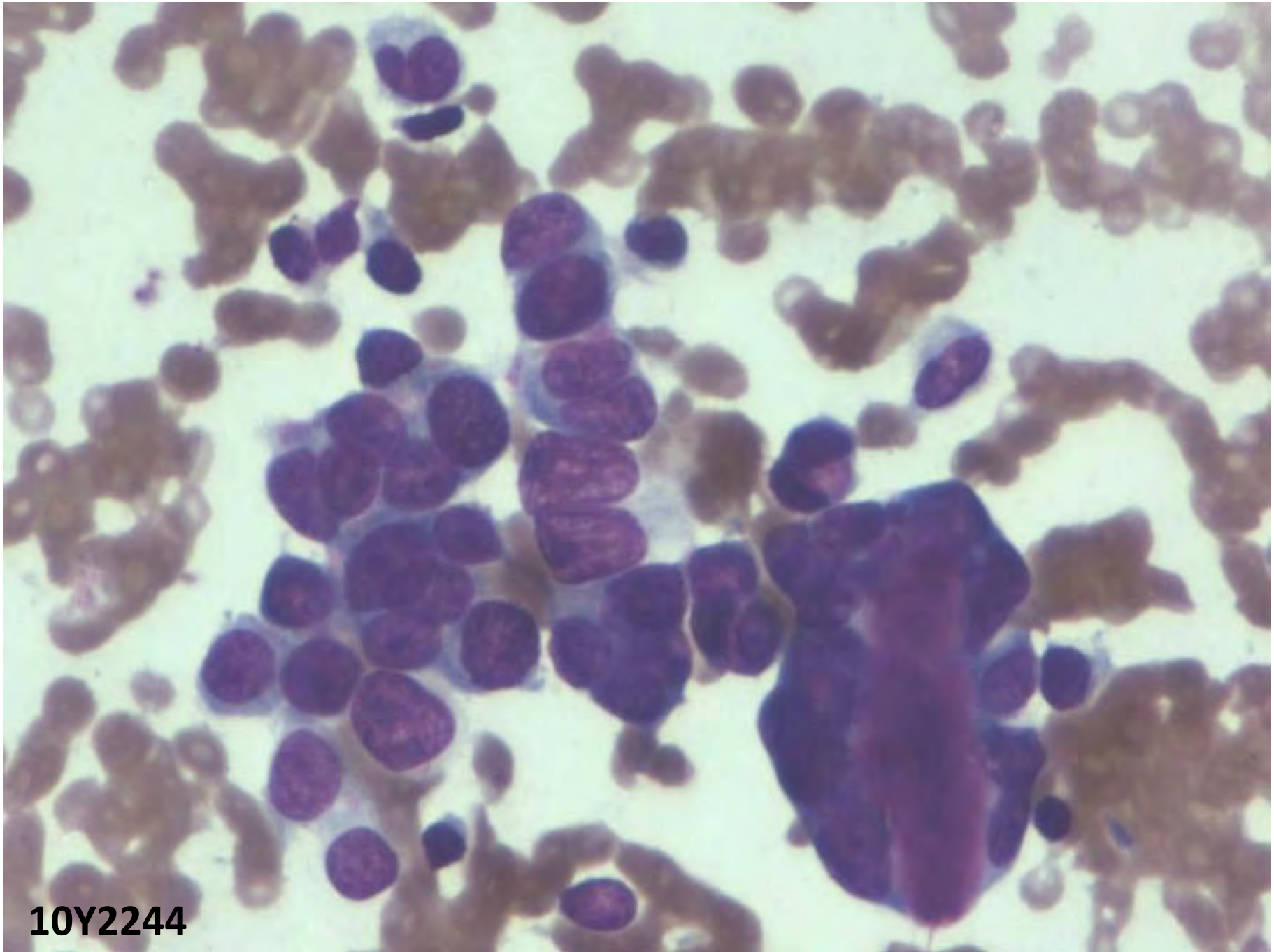
- M/64yrs
- Swelling medial canthus of (R) eye
- 2 X 2 cm, macular, nodular, soft in consistency, mobile
- ?Retention cyst ? infective



10Y2244



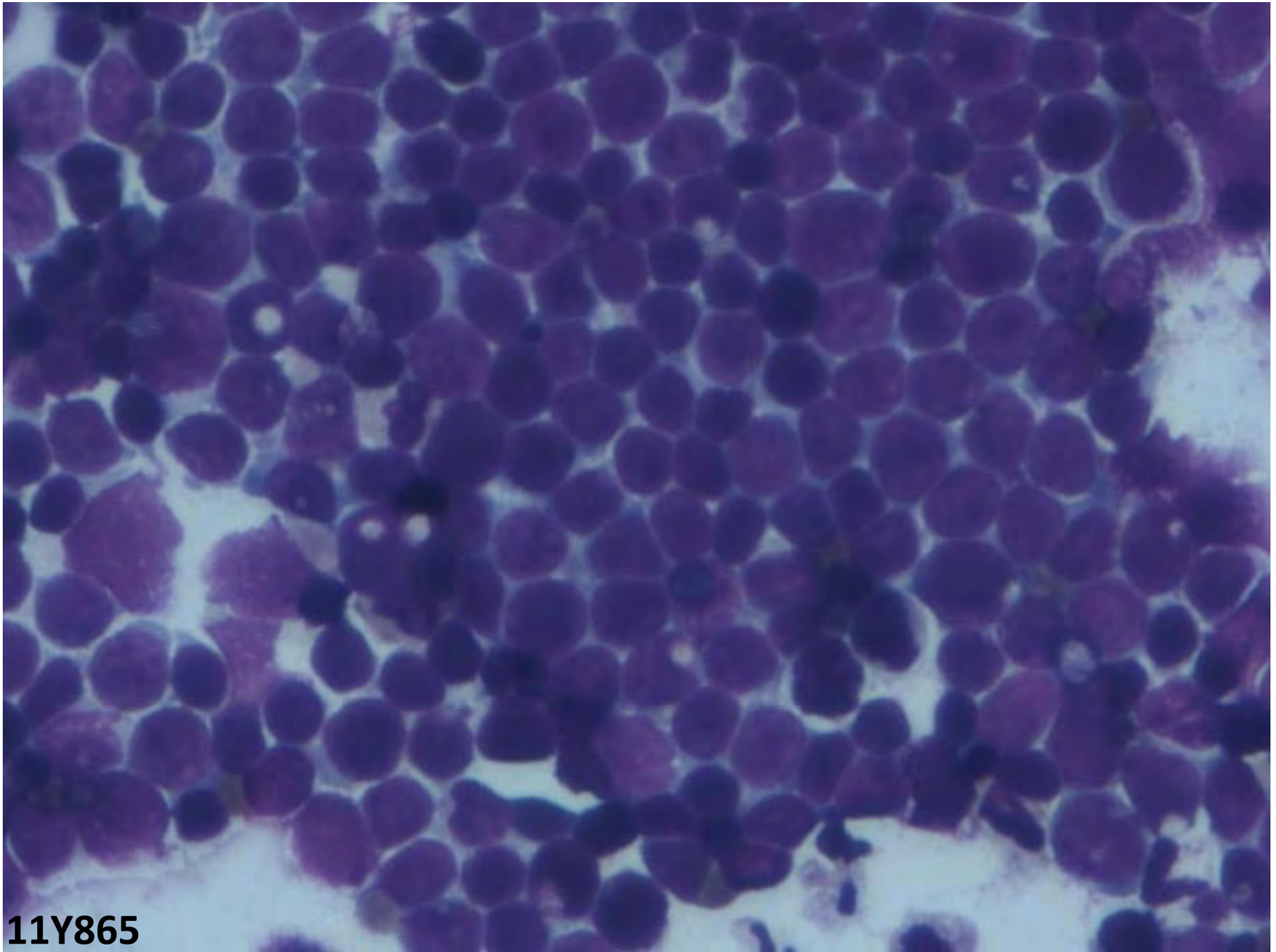
10Y2244



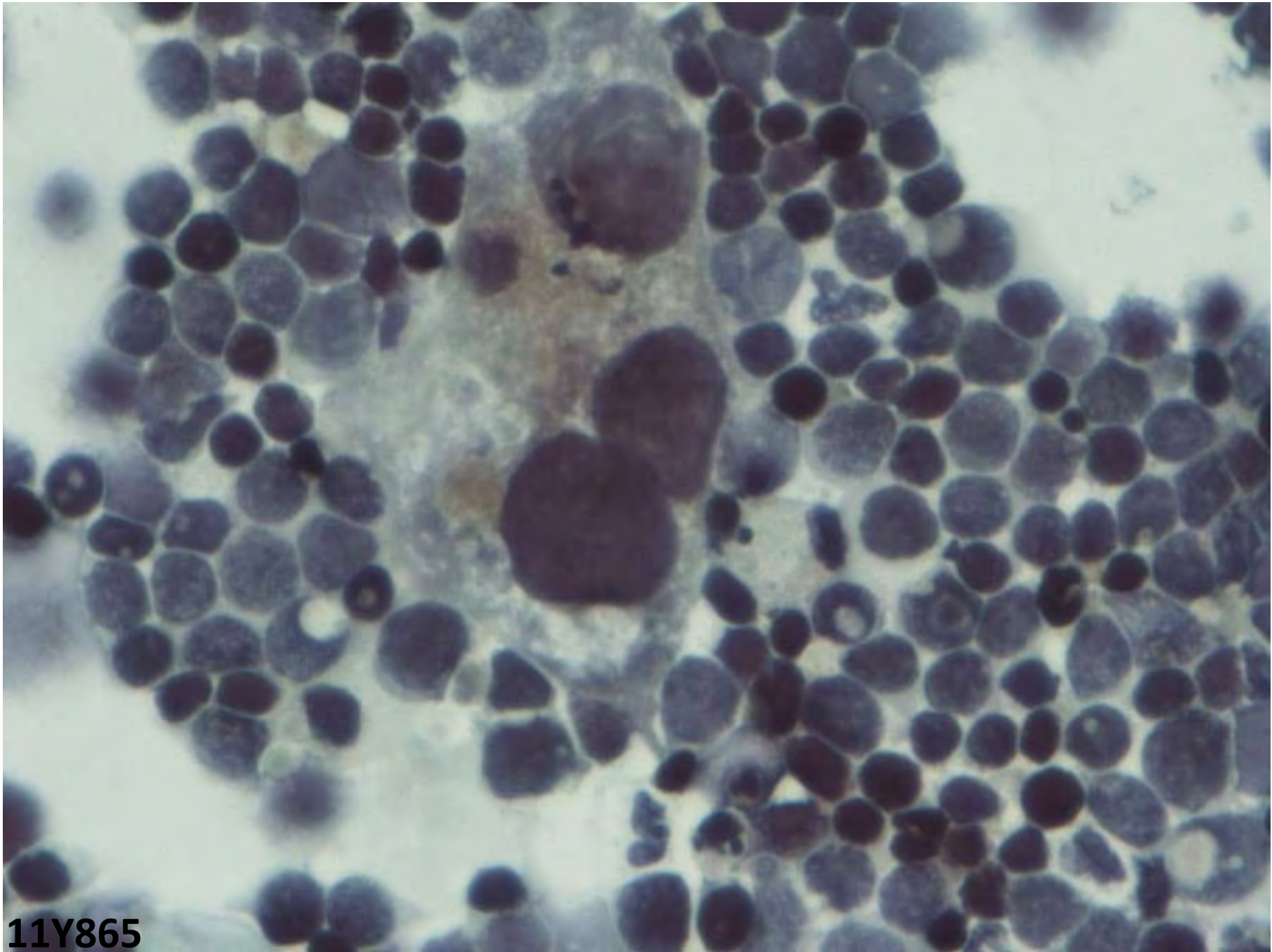
10Y2244

Case 11

- F/ 70yrs
- H/O Carcinoma cervix- 15yrs back
- Treated with RT
- Recurrent ca vault, infiltrating the urinary bladder
- Urine cytology



11Y865



11Y865

Case 12

- 58/F
- Lump Rt breast and left axillary swelling:
6months
- Mammogram: BIRAD III
- MRI 2X1.5 cm mass in Rt breast: UOQ

Sc 3
TIR/M
SI 7

22.94/11

cm

5 cm

head

FH 0 head

